

# Care of the Patient Undergoing Sex Reassignment Surgery (SRS)

Cameron Bowman, M.D., F.R.C.S.C.\*  
Joshua Goldberg<sup>§</sup>

January 2006



*a collaboration between Transcend Transgender Support & Education Society and Vancouver Coastal Health's Transgender Health Program, with funding from the Canadian Rainbow Health Coalition's Rainbow Health – Improving Access to Care initiative*

---

\* Clinical Instructor, Plastic & Reconstructive Surgery, University of British Columbia, Vancouver, BC, Canada;  
SRS Fellow, University Hospital of Gent, Belgium

<sup>§</sup> Education Consultant, Transgender Health Program, Vancouver, BC, Canada



# Table of Contents

Scope.....	1
Development of a Local SRS Program .....	1
Guidelines for the Recommendation of SRS.....	2
Harry Benjamin International Gender Dysphoria Association's Standards of Care.....	2
BC Medical Services Plan requirements for surgical coverage.....	4
Regret following SRS.....	4
Feminizing Surgery (Male-to-Female).....	5
Surgical procedures .....	5
Augmentation mammoplasty (breast augmentation) .....	5
MTF genital reconstruction .....	6
Vaginoplasty .....	6
Orchiectomy without vaginoplasty .....	7
Penectomy without vaginoplasty .....	7
Facial feminizing surgery .....	7
Voice pitch-elevating surgery.....	8
Other feminizing surgical procedures.....	8
Suggested timelines and sequencing .....	8
Expected course and recovery.....	8
Risks and complications.....	11
Revisional surgery .....	14
Masculinizing Surgery (Female-to-Male).....	15
Surgical procedures .....	15
FTM chest surgery.....	15
Subcutaneous mastectomy .....	15
Breast reduction .....	17
Hysterectomy and oophorectomy .....	17
FTM genital reconstruction .....	18
Vaginectomy and urethral lengthening .....	18
Metaidoplasty.....	18
Phalloplasty .....	18
Scrotoplasty.....	19
Other masculinizing surgeries.....	20
Suggested timelines and sequencing .....	20
Expected course and recovery.....	21
Risks and complications.....	23
Revisional surgery .....	26
Conclusion .....	26
References.....	27
Appendix A: Resources.....	35

# Care of the Patient Undergoing Sex Reassignment Surgery (SRS)

## Scope

Sex reassignment surgery (SRS) has proven to be an effective intervention for the patient with gender dysphoria. Patient satisfaction following SRS is high,<sup>1,2</sup> and reduction of gender dysphoria following SRS has psychological and social benefits.<sup>3,4</sup> As with any surgery, the quality of care provided before, during, and after SRS has a significant impact on patient outcomes.<sup>5</sup>

This document is intended to help primary care providers who are already familiar with routine transgender care (as discussed in *Transgender Primary Medical Care: Suggested Guidelines for Clinicians in British Columbia*<sup>6</sup>) to understand the specialized processes involved in SRS. Topics include guidelines for the recommendation of SRS, feminizing and masculinizing surgical procedures, suggested timelines for various interventions, expected course and recovery, risks and complications, and revisional surgery that may be required. Information written specifically for transgender patients, their loved ones, and clinicians unfamiliar with medical terminology (e.g., counsellors) is available from the Transgender Health Program (Appendix A).

These guidelines are not intended to cover the details of operative techniques, nor can they cover every risk, sequella, or complication that might arise. Rather, this document is intended to provide a general orientation for the family physician or nurse whose patient is undergoing SRS. We recommend that clinicians who do not routinely care for transgender individuals but are asked to assist in post-operative care (e.g., home care nurses, hospital nurses, gynecologists) consult with the Transgender Health Program for materials that can provide a more general orientation to transgender care. Consultation with an experienced surgeon is advised when questions surrounding these complex constructive procedures arise.

## Development of a Local SRS Program

Some SRS procedures (e.g., breast augmentation, mastectomy, hysterectomy/oophorectomy) involve relatively minor modification of surgical procedures routinely performed for the non-transgender population. For optimal results, the surgeon should be familiar with trans-specific modification to standard techniques, and according aftercare considerations. While post-operative care following these procedures is usually straightforward and complications are typically easily managed by the primary care provider, surgical consultation may be required.

Genital reassignment surgery is a more complex procedure with multiple trans-specific considerations. In the past there have been no local surgeons with the specialized training and expertise required to perform genital reconstruction, and as a result transgender patients have had to travel out-of-province. Primary care providers with little SRS experience have thus had to coordinate post-operative care and manage post-operative complications with little assistance from the original surgeon (often operating in another country). The lack of coordinated effort to connect surgeons with local primary care providers and other clinicians involved in transgender care has been a difficult situation for both the primary care provider and the patient.

To improve the quality of care, a new SRS program is being created in Vancouver with the aim of offering all SRS procedures within BC. SRS is a multidisciplinary endeavour drawing on plastic surgery, urology, gynecology, reproductive endocrinology, and otolaryngology. Plastic surgeon

Cameron Bowman, who recently completed a fellowship in male-to-female and female-to-male reconstructive procedures, is coordinating the development of an interdisciplinary team similar to those practising in the USA and Europe.<sup>7-9</sup> The local team will provide direct patient care and will also be available for consultation with primary care providers to assist in management of post-operative care after the patient leaves the hospital. Clinical training will also be available for surgical residents with an interest in working with transgender individuals. The program will follow the Harry Benjamin International Gender Dysphoria Association's *Standards of Care*<sup>10</sup> and the protocols described in this document. The Transgender Health Program (Appendix A) will inform patients and clinicians about this program as it develops.

## Guidelines for the Recommendation of SRS

For any type of surgery, all patients must meet general criteria:

- the patient must be physically fit for surgery
- the patient must be psychologically prepared for surgery
- the patient must have realistic goals and expectations of the surgery
- the patient must have a good understanding of the interventions to be performed
- the patient should be informed of, and understand, any alternative procedures
- risks and complications of the interventions must be reviewed and understood
- the patient must have given their informed consent for the procedures

With some types of surgery (including but not limited to SRS), detailed protocols are used to ensure that surgical treatment is appropriate and that the patient is a suitable candidate. To promote quality care, the Harry Benjamin International Gender Dysphoria Association – an international association with members from surgery, gynecology, urology, endocrinology, family medicine, nursing, psychiatry, psychology, counselling, social work, and other disciplines – develops and publishes guidelines for the evaluation of the transgender patient prior to SRS.

## Harry Benjamin International Gender Dysphoria Association's Standards of Care

The Harry Benjamin International Gender Dysphoria Association (HBIGDA) publishes *Standards of Care* to provide flexible directions for the treatment of gender dysphoria.<sup>10</sup> The *Standards* are intended as minimum guidelines, and may be modified to address a patient's unique anatomic, social, or psychological situation. The *Standards* are revised periodically to incorporate new research findings and clinical techniques, and to address emerging issues in clinical practice.

Key points in the HBIGDA *Standards of Care* relating to SRS include:

### 1. Evaluation by mental health professional(s) prior to SRS

The HBIGDA *Standards of Care* state that prior to chest/breast surgery, at least one mental health professional with specialized training in transgender health should evaluate the patient's eligibility and readiness for SRS. Evaluation by two mental health professionals is required prior to gonadal removal or genital surgery. Qualifications for surgical assessors and guidelines for psychological assessment prior to surgery are discussed in detail in *Counselling and Mental Health Care of Transgender Adults and Loved Ones*.<sup>11</sup>

The mental health professional(s) will provide a letter of documentation outlining the eligibility criteria that have been met and the rationale for recommending SRS. *Eligibility* refers to the minimum

criteria that anyone seeking these medical interventions must meet, and *readiness* refers to the client being mentally ready for the procedure. Readiness does not imply that the client must no longer have any mental health concerns; rather, sufficient stability needs to be in place to both make an informed decision and to be adequately prepared to deal with the physical, emotional, and social consequences of the decision. Table 1 below summarizes the eligibility and readiness criteria in the HBGDA *Standards of Care*.

**Table 1: Summary of the Harry Benjamin International Gender Dysphoria Association's *Standards of Care* eligibility and readiness criteria**

	<b>Eligibility criteria</b>	<b>Readiness criteria</b>	<b>Minimum timeline</b>
<b>Chest/breast surgery</b>	1) Able to give informed consent 2) Informed of anticipated effects and risks 3) Completion of 3 months of "real life experience" OR have been in psychotherapy for duration specified by a mental health professional (usually minimum of 3 months)	1) Consolidation of gender identity  2) Improved or continuing mental stability	FTM chest surgery may be done as first step, alone or with hormones; MTF breast augmentation may be done after 18 months on hormones (to allow time for hormonal breast development)
<b>Genital surgery / hysterectomy</b>	1) Able to give informed consent 2) On hormones for > 12 months (if needing and medically able to take hormones) 3) At least 1 year "real life experience" 4) Completion of any psychotherapy required by the mental health professional 5) Informed of cost, hospitalization, complications, aftercare, and surgeon options		At least one year of "real life experience"

Evaluation by mental health professionals is not required for other types of SRS (e.g., facial feminizing surgery, voice pitch-elevating surgery), but as with any type of surgery the surgeon may ask for the patient to be evaluated by a mental health clinician if there are concerns about co-existing mental health problems or insufficient competency to make medical decisions.

## **2. The surgeon is part of the team of clinicians participating in a long-term treatment process and must understand the basis of the recommendation for genital surgery**

The surgeon will speak at length with the patient to be satisfied that the patient is likely to benefit from the procedures, and will seek to establish a working relationship with the other health care professionals who are involved in the patient's physical and mental health care. This includes coordination of pre- and post-operative care with the patient's primary care provider.

## **3. The surgeon must have specialized competence in SRS**

In addition to Board-certification as a urologist, gynecologist, plastic surgeon or general surgeon, documented supervised training with a more experienced SRS surgeon is required. Surgeons are expected to attend professional meetings where new techniques are presented.

Ideally, the surgeon will be knowledgeable about more than one of the surgical techniques that may be used to facilitate choice of the technique best suited to the patient's individual needs. If the surgeon is skilled in a single technique, the patient should be so informed, and those who do not want or are unsuitable for this procedure should be referred to another surgeon.

#### 4. Physical assessment prior to surgery

Assessment of physical health and investigation of any medical conditions of concern are standard pre-operative procedures. Prior to SRS, assessment should include evaluation of the effects of endocrine therapy on the liver and other organ systems. The HBGDA *Standards of Care* explicitly state that it is unethical to deny SRS solely on the basis of HIV or Hepatitis B/C seropositivity. Decisions about SRS suitability should be made based on a comprehensive evaluation of the patient's overall health, not on seropositivity alone.<sup>12,13</sup>

#### BC Medical Services Plan requirements for surgical coverage

The BC Medical Services Plan (MSP) has criteria beyond those in the HBGDA *Standards of Care* for individuals seeking public health coverage to assist with the costs of SRS. To qualify for MSP surgical coverage, the patient must have a diagnosis of Gender Identity Disorder, two mental health clinicians appointed by the Medical Services Plan must recommend surgery, and a two-year "real life experience" must be completed (regardless of the type of surgery). The coverage provided and documentation required by MSP is discussed in greater detail in *Social and Medical Advocacy with Transgender People and Loved ones: Recommendations for BC Clinicians*.<sup>14</sup>

#### Regret following SRS

With any irreversible medical procedure there is a risk of patient dissatisfaction, and primary care providers are often concerned that their transgender patients will experience regret following SRS. To address this concern it is helpful to understand (a) the incidence and causes of post-surgical regret, and (b) protective measures in place to help prevent regret following SRS.

*Temporary* concerns are relatively common after any surgery, and (in both the transsexual and non-transsexual literature) typically relate to post-operative pain, surgical complications, discrepancy between hoped-for results and actual results, and initial difficulty adjusting to the impact of surgery on immediate relationships.<sup>2</sup> Dissatisfaction, disappointment, doubt, or other psychological difficulties that represent normal adjustment and resolve (spontaneously or with psychotherapeutic assistance) in the first year after surgery are distinguished from a persistent wish that surgery had not been pursued.

*Persistent* regret is more rare following surgery, and may (for reversible surgeries) be accompanied by a request for surgical reversal. In studies of non-transsexual individuals who reported regret following a variety of surgical procedures (including surgical sterilization,<sup>15-19</sup> mastectomy,<sup>20-25</sup> breast reconstruction,<sup>23,26</sup> breast augmentation,<sup>27-29</sup> oophorectomy,<sup>30</sup> orchiectomy,<sup>31</sup> limb salvage surgery,<sup>32</sup> gastric banding,<sup>33</sup> and colpocleisis<sup>34</sup>), the regret rate ranged from <1% to 23%. The reported reasons for regret included adverse physical effects of surgery, loss of physical functioning, poor aesthetic result, failure to achieve desired effect, lack of support available before and after surgery, change in intimate relationship, psychological issues not recognized prior to surgery, and incongruence between patient preferences regarding decision involvement and their actual level of involvement.

Persistent regret among post-operative transsexuals has been studied since the early 1960s. The most comprehensive meta-review done to date analyzed 74 follow-up studies and 8 reviews of outcome studies published between 1961 and 1991 (1000-1600 MTF and 400-550 FTM patients).<sup>3</sup> The authors concluded that in this 30 year period, <1% of female-to-males (FTMs) and 1-1.5% of male-to-females (MTFs) experienced persistent regret following SRS. Studies published since 1991 have reported a decrease in the incidence of regret for both MTFs and FTMs that is likely due to improved quality of psychological and surgical care for individuals undergoing sex reassignment.<sup>1,5,35-39</sup>

Numerous studies have explored clinical practices that may help in the prevention of regret following SRS, and negative prognostic factors. There are three key factors in persistent regret following SRS: (a) incorrect diagnosis of gender dysphoria or of co-existing psychopathology, (b) poor quality of surgical intervention, and (c) lack of ability to live in the desired gender role.<sup>2,5,40</sup> The latter issue is influenced by numerous psychosocial issues, including lack of support by loved ones, psychological dysfunction, fluctuating gender identity, and insufficient professional support during treatment.<sup>35,37,40</sup> None are considered absolute contraindications for SRS, but all are considered risk factors that warrant careful clinical attention. The HBIGDA *Standards of Care* require “real life experience” (RLE) in the desired gender role as part of the pre-surgical evaluative process prior to genital surgery or gonadal removal. The RLE provides an opportunity to evaluate the impact of transition on the patient’s support network (loved ones, friends, etc.), and the impact of the stresses of transition on the patient’s psychological resilience.

Inaccurate diagnosis of gender dysphoria or co-existing psychopathology and poor quality of the surgical intervention relate to clinical competence for mental health professionals and surgeons involved in transsexual care. The HBIGDA *Standards of Care* outline competency requirements for clinicians involved in SRS, and HBIGDA also provides opportunities for scientific interchange among professionals through its biennial conferences, publications, and email discussion lists. The Transgender Health Program (Appendix A) coordinates training for surgical assessors who have the professional credentials required by HBIGDA and the BC Medical Services Plan.

As discussed above, the HBIGDA *Standards of Care* state that pre-operative counselling is at the discretion of the mental health professional(s) conducting the assessment of surgery eligibility and readiness. While psychotherapy is not an absolute requirement for SRS, supportive professional and peer counselling can be helpful with preparation and adjustment, and should be accessible to all patients before and after surgery. The primary care provider can assist by discussing patient awareness of resources and, where needed, facilitating referrals to trans-experienced professionals.

## **Feminizing Surgery (Male-to-Female)**

### **Surgical procedures**

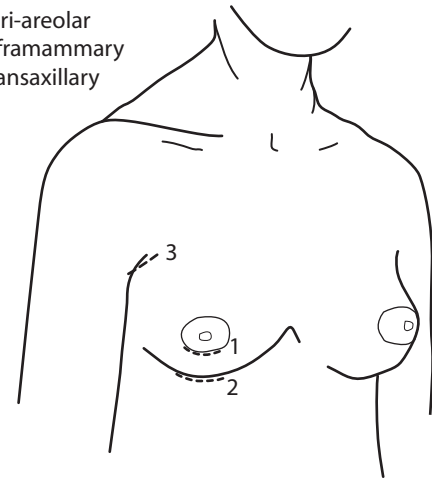
#### *Augmentation mammoplasty (breast augmentation)*

Feminizing hormonal therapy often effects some breast development. However, this is not always sufficient for the MTF patient to live comfortably. In these cases surgical augmentation/reconstruction may be recommended. Breast augmentation is a common procedure which is performed by the plastic surgeon. It will usually be delayed until after hormonal therapy has been undertaken for a period of 18 months to allow time for maximal hormonal breast development. Breast augmentation is therefore sometimes performed simultaneously with vaginoplasty.

Breast augmentation is most often performed using saline-filled implants placed sub-muscularly via an incision under the breast (near the inframammary fold) or around the areola. Although the technique is essentially the same as augmentation mammoplasty in non-transgender women, there are important anatomical differences in male and female chests that guide modification for the MTF transsexual. Compared to non-transgender women, the breast envelope of the MTF patient is often undeveloped and tight and there may be less lipomatous tissue.<sup>41</sup> A staged approach involving initial tissue expansion (as in reconstruction following mastectomy) is sometimes used for optimal results.<sup>8</sup>

Augmentation incisions

- 1 Peri-areolar
- 2 Inframammary
- 3 Transaxillary



As discussed in *Endocrine Therapy for Transgender Adults in British Columbia: Suggested Guidelines*,<sup>42</sup> there is no clinical consensus on the best way to promote nipple and breast development in transgender women. Results vary, but in general, the nipple-areola complex appears under-developed and lateralized even after years of hormone treatment. Even after two years of feminizing hormones MTF breast development typically corresponds to the conical shape seen in young adolescents, without the ptosis normally seen as a result of aging. The patient should be made aware that implants cannot perfectly imitate adult breasts. In particular, the age-related changes seen in non-transgender women and cleavage between the breasts is very difficult to create.<sup>41</sup>

## MTF genital reconstruction

### 1. Vaginoplasty

The term vaginoplasty includes several procedures which transform the male external genitalia into female genitalia. The goals of vaginoplasty include:<sup>25,43-47</sup>

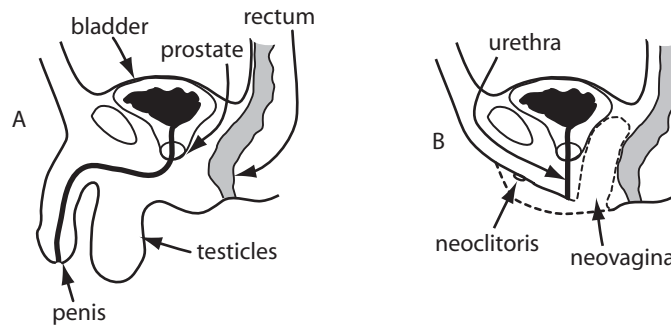
- creation of a sensate and aesthetically acceptable vulva (including clitoris, labia minora and majora, and vaginal introitus)
- shortening of the urethra, with creation of a urethral opening that allows a downward urinary stream
- creation of a stable and sensate neovagina with adequate dimensions for penetrative sexual intercourse, ideally lined with moist, elastic, hairless epithelium
- elimination of erectile tissue (to avoid narrowing of the introitus and protrusion of the urethral meatus/clitoris during sexual arousal)
- preservation of orgasmic capability

Vaginoplasty includes orchiectomy, creation of a vaginal cavity and neoclitoris, labiaplasty, and penile dissection with partial penectomy. It is usually performed by the plastic surgeon in a single operative setting, although some surgeons prefer to perform labiaplasty and clitoroplasty as a second surgery following healing of the initial vaginoplasty.

The penile inversion technique is most commonly used to create the neovagina.<sup>7,44,46-49</sup> In this technique the majority of skin from the shaft of the penis is inverted and used to line the inner walls of the neo-vagina. In some cases, extra skin is required to line the inner vagina. This is usually harvested from the patient's lower abdomen, or scrotal skin grafts may be used.<sup>7,49,50</sup> Use of a segment of the colon (rectosigmoid pedicled transplant) is the third choice if penile inversion or skin grafts from other locations fail.<sup>7,44,48,51,53</sup>

A portion of the horizontal part of the urethra is preserved and used to fashion the female urethra and surrounding tissue. The neovagina is positioned posterior to the prostate (which is untouched).

Labia minora are constructed from prepuce or penile skin, and labia majora are constructed from scrotal skin.<sup>45-47,50,54</sup> In the sensate pedicled clitoroplasty technique, a small portion of the glans is preserved by maintaining attachments to its nerve and blood supply.<sup>47,50,54-57</sup> This then functions as the neo-clitoris. Revisions may be performed after the vaginoplasty to refine the appearance of the clitoris, labia, or the superior aspect of the labia majora (anterior commissure). This is discussed further in the section on revisions on page 14.



## 2. Orchiectomy without vaginoplasty

Orchiectomy as a single procedure may be sought by patients who would like to reduce the risks and side effects of feminizing hormones by lowering the dosage needed to oppose endogenous testosterone.<sup>54,58,59</sup> Typically the testes are removed with preservation of scrotal skin in case vaginoplasty/labiaplasty are sought in the future,<sup>13</sup> but there is risk of shrinkage or damage of the skin. Accordingly, some surgeons recommend against orchiectomy as a separate procedure for the patient who wishes to pursue vaginoplasty at a later date; others feel the benefits of early orchiectomy outweigh the potential risks.<sup>59</sup>

## 3. Penectomy without vaginoplasty

Some MTF patients seek penectomy without vaginoplasty (also known as “nullification”) as a less invasive alternative when vaginal penetration is not desired by the patient. A shallow vaginal dimple is created that does not require dilation (as in vaginoplasty), and a new urethral opening is created to allow the patient to urinate in a sitting position. As penile tissue is typically used in vaginoplasty, penectomy as a separate procedure is not recommended if the patient wishes to pursue vaginoplasty at a later date.

## *Facial feminizing surgery*

Drawing on techniques from soft tissue plastic surgery, maxillofacial surgery, and reconstructive surgery, facial feminizing surgery techniques were pioneered by maxillofacial surgeon Douglas Ousterhout in the USA<sup>60-62</sup> and are now widely available. Facial feminizing surgery involves the use of one or more procedures to reduce stereotypically masculine features and impart more conventionally feminine features to the patient’s head and neck region.<sup>7,13,48,63-66</sup> Facial feminizing surgery procedures include, but are not limited to: removal of supra-orbital bossing (“brow bossing”) and orbital rim contouring, brow elevation, rhinoplasty, ear pinning, augmentation of the lip vermilion area, cheek augmentation, widening of the zygomatic complex, chin/jaw reduction, clockwise rotation of the bimaxillary complex, and reduction laryngochondroplasty (also known as “tracheal shave” or “Adam’s apple reduction”).

## *Voice pitch-elevating surgery*

Surgical alteration of the laryngeal framework and/or vocal cords is sought by some transsexual women who have not been able to sufficiently elevate pitch through speech therapy alone.<sup>48,67-75</sup> Techniques, risks/complications, and outcome data are discussed in *Transgender Speech Feminization/Masculinization: Suggested Guidelines for BC Clinicians*.<sup>76</sup>

## *Other feminizing surgical procedures*

Other surgical procedures to reduce masculine features and approximate a female habitus include suction-assisted lipoplasty of the waist and augmentation of the hips or buttocks.<sup>48,61,62</sup> Hair transplantation may also be desired.<sup>61</sup> As these are not trans-specific procedures, they will not be discussed in these guidelines. Post-operative care protocols are the same as for the non-transgender population.

Removal of the eleventh and twelfth rib is sought by some MTFs to create a more defined waist, but this surgery is not recommended as potential complications include damage to lower chest wall rigidity and impairment of lower lung inflation.<sup>13</sup>

Injection of free (gelatinous) silicone is extremely hazardous. Use of free silicone is not legal in many countries (including Canada and the USA), but may be performed by nonmedical personnel.<sup>13,77</sup> Any patient who has undergone free silicone injection as part of breast augmentation or contouring of hips, buttocks, or the face should be referred for immediate medical evaluation, as effects of free silicone injection include severe disfigurement, neurological impairment, pulmonary disease (including embolism), and death.<sup>77-83</sup>

## **Suggested timelines and sequencing**

Vaginoplasty is a shorter and less complex intervention than phalloplasty. As such, it is safe (and even desirable) to perform both breast augmentation and vaginoplasty within the same operative setting.<sup>41-84</sup> Doing so minimizes the risks associated with general anesthesia. However, the surgeries may also be performed separately.

With the exception of tracheal shaves, most facial feminizing surgical procedures may be performed safely 3 months before or after the vaginoplasty, provided there are no complications. If forehead surgery and rhinoplasty are both sought, it is recommended they be performed together.<sup>61</sup> Electrolysis treatment should be stopped completely at least two weeks prior to facial surgery and should not be resumed sooner than three months following chin or jaw surgery.<sup>61</sup>

Pitch-elevating surgery should be performed last in the sequence of feminizing surgeries as some types of pitch-elevating surgery narrow the trachea, making endotracheal intubation more difficult. Endotracheal intubation may also destabilize recently altered vocal cords.<sup>7</sup>

## **Expected course and recovery**

### *Pre-operative*

Following receipt of letters of recommendation and an initial interview with the surgeon to determine appropriateness of SRS, the MTF patient will meet with the surgical team. A history and physical examination will be performed. It is most helpful if the general practitioner provides a letter reviewing the pertinent past medical history of the patient. A discussion outlining the patient's goals will be

undertaken and a timeframe for the various interventions will be established following the guidelines of the surgical team and the HBGDA *Standards of Care*. The specific procedures will be outlined with the patient, including the possible need for harvesting extra skin to line the neo-vagina as well as the expected course and recovery period. Risks and complications will be reviewed. To prevent intravaginal hair growth from use of hair-bearing grafts (scrotal skin, base of penis), patients undergoing vaginoplasty will be provided with referral information for clinicians with experience in MTF genital electrolysis.

The effects of smoking on skin quality, wound healing, and vascularity will be discussed and patients will be strongly encouraged to stop smoking. Smoking cessation resources will be identified.

In conjunction with the prescribing physician, feminizing endocrine therapy is stopped 2 to 4 weeks pre-operatively (depending on the specific medication and its route of administration). Medications affecting the coagulation cascade must be stopped 7-10 days prior to surgery. Prior consultation with an appropriate physician is required in the case of complicating medical factors.

### *Peri-operative*

The patient undergoing breast augmentation as a single surgery will be admitted and, in most cases, be discharged home the same day as surgery. Patients will take nothing by mouth (with some exceptions for medications) after midnight the night prior to surgery. While in hospital, patients will have routine monitoring by the nursing and surgical staff and residents. Pain management is usually straightforward, allowing for early discharge home with oral analgesics. Antibiotics are usually given in hospital.

In the case of a vaginoplasty, patients are admitted the day prior to surgery. They will undergo a "bowel prep" (including phosphosoda and antibiotics) to cleanse the bowel of particulate matter, and will take nothing by mouth after midnight. Blood will be drawn and an electrocardiogram will be obtained. Occasionally, a chest x-ray is taken. Patients will undergo pre-operative shaving prior to their surgery.

The course in hospital will average 6 to 8 days and the patient will remain on bedrest restriction for much of this time. Patients may use PCA (patient controlled analgesia) and will typically remain on parenteral anti-coagulants and antibiotics until the patient is mobile. A prosthesis will be placed into the neo-vagina at the time of surgery and will be left in place for 5 days to ensure the penile skin flap (+/- graft) will be well apposed to the inner vaginal walls in maximum dimensions. After this, the prosthetic device and Foley catheter will be removed and the patient will be instructed in the routine care of the neo-vagina. For the next several weeks the prosthesis will be left in place much of the time, being removed only occasionally for routine douching.

Peri-operative recovery from facial feminizing surgery depends on the specific techniques used (particularly the degree of bone revision vs. soft tissue work). Minor procedures may be performed on an outpatient basis with same-day discharge; more extensive bone reconstruction will likely be done on an inpatient basis with discharge the following day.<sup>61</sup>

### *Post-operative*

#### **1. MTF augmentation mammoplasty**

Patients who have undergone a breast augmentation will wear an underwire bra and leave their dressings intact for 3 days following surgery. After this, the gauze dressings may be removed but the steri-strips along the incision lines should be left in place. The patient may then shower, taking care

to avoid soaking the incisions. The steri-strips should be gently patted dry and will fall off on their own in 7 to 10 days.

It is normal for incisions to be erythematous, but this erythema should not extend or progress to more than 1 to 2 cm from the incision. It is also normal to see or feel the suture knot at the end of the incision line. These superficial suture knots can be a nuisance; however, they are not a cause for concern. If they work their way to the surface (usually around 3 weeks) they can be clipped free. Bruising and swelling is expected and is not a cause for concern unless there is an unusually large amount of swelling (mass) on one side. Feelings of sharp shooting pain, burning sensations, and/or general discomfort are common during the healing process and will eventually disappear.

Patients are usually comfortable 1 or 2 days following the procedure and often back to their daily routine in 1 to 2 weeks (this is variable). However, strenuous activity should be avoided for 3 to 4 weeks. Patients will be instructed in implant displacement exercises (breast massage) which should be started 3 to 5 days following surgery, if tolerated.

## **2. MTF genital reconstruction**

Patients who have undergone a vaginoplasty will begin to feel more comfortable during the second post-operative week. The prosthesis will be left in place, only being removed for routine cleaning once per day initially. The amount of time the prosthesis is left out will gradually be increased over the next 8 weeks (a written protocol will accompany the patient home). After that, it should be used periodically (once per day) if the patient is not engaging in regular sexual vaginal penetration. Daily dilation is necessary to prevent vaginal stricture: insufficient dilation can lead to loss of vaginal depth and width.

The patient will be asked to follow up in the clinic in the week following vaginoplasty, and then periodically after that. She will have a physical examination, including a manual pelvic exam to ensure viability of the skin flap and patency of the neo-vagina. The neo-clitoris is inspected for viability and sensation. The quality of wound healing is assessed (dehiscence, infection or hypertrophic scarring). In addition, bowel and bladder function is queried.

If skin grafts are required, full thickness grafts may be taken above the pubic area or the flank area at both sides. There will most likely be a transverse incision just above the pubic region, with steri-strips in place. Graft donor sites should be inspected at the first visit with the primary care provider for the absence of infection and wound healing problems.

As discussed in *Transgender Primary Medical Care: Suggested Guidelines for Clinicians in British Columbia*,<sup>6</sup> following vaginoplasty the MTF patient is still at risk for prostate cancer, as the prostate is not removed. The patient should be made aware of this risk and informed of screening recommendations.

## **3. MTF facial feminizing surgery**

Post-operative recovery from facial feminizing surgery depends on the specific procedure (particularly the degree of bony vs. soft tissue work) and techniques used. The following protocols are used by Dr. Douglas Ousterhout, the originator of facial feminizing surgery.<sup>61</sup>

- a) *Forehead surgery* (scalp advancement, brow elevation, removal of supraorbital bossing, orbital rim contouring)

The dressing placed around the forehead after surgery can be removed the day following surgery. Gentle washing of the hair can then commence, with care taken not to wet any supporting dressings used for simultaneous nose or chin surgery. Pain medication and antibiotics will be prescribed.

Swelling and bruising around the eyes typically resolves within 10-12 days following surgery. Patients are typically able to return to work within seven days following surgery, but it is not advisable to perform any activities that require exertion until two weeks after surgery. Sutures and staples used to close scalp incisions are usually removed within eight days following surgery.

b) *Cheek augmentation*

Pain medication and antibiotics will be prescribed. Temporary numbness and swelling may interfere with speaking, smiling, yawning and chewing for the first 1-3 days following surgery and it is advisable to avoid foods requiring substantial biting or chewing for the first two weeks. Swelling typically completely resolves within two weeks following surgery. The teeth can be cleaned as normal, with care not to disturb the incision line if the implant has been placed through the mouth.

c) *Rhinoplasty*

Internal nasal packing typically remains for 1-2 days to support nasal tissues during the early phase of healing. There will be an external cast on the nose for eight days following surgery; care must be taken not to wet this dressing when bathing. Pain medication will be prescribed. Ecchymosis around the nose and eyes typically fades within two weeks of surgery. If glasses are required, special instructions will be given as the nasal pads that support glasses cannot touch the nose until one month after surgery. Activities that involve exertion should not be performed until one month after surgery.

d) *Chin reduction*

Chin reduction usually requires significant bony work so recovery can take 4-5 weeks, with swelling remaining beneath the mandible for 3-4 months. The patient can typically return to light work within five to six days of surgery.

e) *Jaw reduction*

The face is typically moderately swollen and bruised following jaw reduction. Swelling gradually resolves over 10-14 weeks and the surgical results are often not apparent until the new contour has resolved 3-4 months after surgery. The patient can typically return to work within 10-14 days of surgery.

f) *Lip augmentation*

Most postoperative swelling following augmentation of the vermilion area of the upper/lower lip resolves within 10-14 days of surgery.

## **Risks and complications**

General risks related to operative procedures include deep vein thrombosis, pulmonary embolism, and death. Obviously, these are very serious complications and surgeons, anesthesiologists and nurses take various measures to reduce associated risk. These include I.V. hydration, active monitoring, the use of compression stockings and/or pneumatic compression devices, judicious anticoagulation, and early mobilization. Once home, patients should stay well-hydrated and should not remain in bed for extended periods. Tender, warm, or swollen legs; chest pain; or continued dizzy spells should be investigated in the E.R. If a patient experiences sudden shortness of breath, emergency medical assistance should be sought.

Risks and complications specific to each surgical feminization procedure (or group of procedures commonly performed together) are discussed below.

### 1. MTF augmentation mammoplasty

Risks associated with augmentation mammoplasty include wound infection; post-operative bleeding/hematoma; capsular contracture (thickening and contracture of scar tissue which naturally forms around the breast implant); asymmetry of breast size, shape, or position; asymmetry of the nipple-areola complex; and implant failure, infection, or extrusion.<sup>41,84,85</sup> Scar management (including massage and sun avoidance) will be discussed with the patient; hypertrophic scarring is possible due to intrinsic or extrinsic factors. Decreased sensation to the nipple-areola complex is common and usually resolves spontaneously within a few weeks (occasionally months). Partial or permanent loss of nipple or skin sensation may occur. Visible and palpable wrinkling of the implant can occur, and is more likely if breast development has been minimal after hormone treatment and/or the patient is thin.

Management of complications relating to MTF augmentation mammoplasty is discussed in the table below.

**Table 2: Management of complications following MTF augmentation mammoplasty**

Complication	Signs and symptoms	Treatment
Post-operative bleeding/hematoma	expanding painful mass on one side	<ul style="list-style-type: none"> <li>expanding hematoma will need to be evacuated, and the bleeding stopped, in the O.R.; in most cases the implant can be saved and replaced at that time</li> </ul>
Infection	blanching erythema which spreads beyond the incisional margins, combined with tenderness, fever, malaise, and leukocytosis	<ul style="list-style-type: none"> <li>small infections: course of antibiotics</li> <li>abscesses: often need to be drained in the O.R. or under ultrasonic guidance</li> <li>persistent infections (caused by multidrug-resistant organisms): consult surgeon</li> <li>infection within the breast implant pocket necessitates removal of the implant; after the infection is treated, a new implant can be placed at a later date</li> </ul>
Seroma	gradual and progressive swelling of the breast due to fluid accumulation	<ul style="list-style-type: none"> <li>usually resolve with time</li> <li>may require aspiration (1 or more times) by surgeon</li> </ul>
Wound healing problems	most often small dehiscences due to stitch rupture or minor infection	<ul style="list-style-type: none"> <li>if minor, treat with basic wound care: dressing changes, antibiotic ointment</li> <li>if incision line is progressively opening such that the wound is gaping, contact the surgeon</li> </ul>
Asymmetry	asymmetrical breast size, shape, or position, or asymmetrical positioning of the nipple-areola complex	<ul style="list-style-type: none"> <li>revisional surgery after re-evaluation following resolution of swelling and implant settling (4-6 months)</li> </ul>
Capsular contracture	excessive firmness of the breasts and shape distortion, shortly after surgery or many years after, on one or both sides	<ul style="list-style-type: none"> <li>surgical removal of thickened capsule, with implant replacement or removal</li> </ul>
Implant extrusion	exposure of implant caused by infection, wound healing problems, or lack of tissue coverage	<ul style="list-style-type: none"> <li>removal and replacement at a later date</li> </ul>
Implant failure	sudden change in size or shape of breast	<ul style="list-style-type: none"> <li>removal and replacement of damaged implant</li> </ul>
Hypertrophic scarring		<ul style="list-style-type: none"> <li>prevention: sun avoidance, massage</li> <li>severe scarring may require surgical revision</li> </ul>

## 2. MTF genital reconstruction

Risks of MTF genital reconstruction using the penile inversion method include infection; post-operative bleeding/hematoma; recto-vaginal fistula; partial or complete flap necrosis; vaginal or urethral stricture or stenosis; prolapse of the neovagina; and unsatisfactory size/shape of the neovagina, clitoris, or labia.<sup>8,45,49,50,54,86,87</sup> Scar management will be discussed with the patient; hypertrophic scarring is possible due to intrinsic or extrinsic factors. If the patient has not undergone epilation of the donor site prior to vaginoplasty, the use of hair-bearing tissue to create the neovagina may result in intravaginal hair growth.<sup>13,49</sup>

Partial or complete flap necrosis (leading to loss of the clitoris) is a devastating complication which, thankfully, is a rare occurrence.<sup>45,49</sup> Vascular compromise would most likely occur in the early post-operative period. By the time the patient is discharged home the risk of total flap failure is quite low.

Decreased erogenous sensation is a potential risk of vaginoplasty, but sexual outcomes are generally good. At followup (mean 4.2 years after surgery) of 71 MTFs who underwent vaginoplasty at Gent University Hospital between 1998 and 1999, erogenous sensation was present in all but one patient (98.6%), and 94% of patients reported achieving orgasm at least occasionally.<sup>7</sup> Other studies report orgasmic capability among 63-92% of MTFs following vaginoplasty.<sup>38,39,45,51,54,88</sup> A study of 14 MTFs found that although self-reported orgasmic capacity decreased following vaginoplasty, reported frequency of sex increased by 75% and sexual satisfaction remained high.<sup>89</sup>

Management of complications relating to MTF genital reconstruction is discussed in the table below (continuing on the following page).

**Table 3: Management of complications following MTF genital reconstruction**

Complication	Signs and symptoms	Treatment
Post-operative bleeding/hematoma	ongoing bleeding and swelling at the operative site immediately following surgery	<ul style="list-style-type: none"> <li>will be managed by hospital staff</li> </ul>
	bleeding in first few weeks (typically following dilation)	<ul style="list-style-type: none"> <li>minor bleeding after dilation can be controlled by applying pressure to the site</li> <li>surgeon should be consulted if there is recurrent bleeding</li> </ul>
	persistent bloody or purulent discharge with dilation	<ul style="list-style-type: none"> <li>weekly application of silver nitrate to areas of granulation tissue until area re-epithelializes</li> <li>uterine/bone curette may be used to scrap areas with profuse granulation</li> </ul>
Infection	progressive pain and blanching erythema which spreads beyond the incisional margins, combined with tenderness, fever, malaise, and leukocytosis	<ul style="list-style-type: none"> <li>small infections: course of antibiotics</li> <li>abscesses: often need to be drained in the O.R. or under ultrasonic guidance</li> <li>persistent infections (caused by multidrug-resistant organisms): consult surgeon</li> </ul>
Wound healing problems	most often small dehiscences due to stitch rupture or minor infection	<ul style="list-style-type: none"> <li>if minor, treat with basic wound care: dressing changes, antibiotic ointment</li> <li>if incision line is progressively opening such that the wound is gaping, contact the surgeon</li> </ul>
Recto-vaginal fistula	gas or feces passing from the vagina due to communication between neovagina and rectum; fistula confirmed by speculum examination or contrast X-ray study	<ul style="list-style-type: none"> <li>surgical repair</li> </ul>

*continued on following page*

Complication	Signs and symptoms	Treatment
Partial or complete flap necrosis (loss of clitoris)	usually presents early with non-blanching erythema or mottling of the skin, which progressively becomes darker and non-viable	<ul style="list-style-type: none"> <li>unusual to happen after discharge from hospital</li> <li>immediate contact with surgeon is required</li> </ul>
Vaginal stricture or stenosis	pain or difficulty with vaginal penetration	<ul style="list-style-type: none"> <li>prevention: lifelong patient dilation (daily)</li> <li>consult with surgeon: treatment options range from progressive dilation to surgical revision</li> </ul>
Urethral stricture or stenosis	dysuria, difficulty voiding, diminished urine stream, increased time and effort required for urination	<ul style="list-style-type: none"> <li>if immediately following removal of Foley catheter, replace catheter for 2-3 more days until swelling around meatus subsides and patient can void spontaneously</li> <li>late stenosis: if minor, dilation with a Foley catheter may suffice; if major, surgical revision may be necessary</li> </ul>
Swelling/irregularities of urethral meatus	urine spraying (rather than steady stream)	<ul style="list-style-type: none"> <li>usually resolves spontaneously within a few months after surgery, as swelling subsides</li> <li>surgical repair may be needed in severe cases</li> </ul>
Prolapse of the neovagina	"falling out" sensation, dyspareunia	<ul style="list-style-type: none"> <li>surgical repair</li> </ul>
Intravaginal hair growth	vaginal irritation or discharge, with hair visible on examination with speculum	<ul style="list-style-type: none"> <li>prevention: epilation of donor site prior to vaginoplasty</li> <li>mechanical removal of intravaginal hair after surgery may only be partially effective</li> </ul>
Hypertrophic scarring		<ul style="list-style-type: none"> <li>severe scarring may require surgical revision</li> </ul>

### 3. MTF facial feminizing surgery

Risks of facial feminizing surgery include infection of the wound or implants, numbness due to edema (transient) or nerve damage (potentially permanent), and dissatisfaction with the aesthetic results.<sup>61</sup> Following rhinoplasty there may be a mild scleral hemorrhage and edema around the nose which typically resolves spontaneously after several weeks. Prophylactic antibiotics may be prescribed to prevent infection; implant infection necessitates removal.

## Revisional surgery

Typical revisions in breast augmentation include, but are not limited to:

- exchanging implants for those of a different size
- exchanging implants for those of a different type
- placing the implants in a slightly different location
- scar revisions

Revisions in vaginoplasty may include, but are not limited to:<sup>7,54,90,91</sup>

- clitoroplasty: adjusting the size, shape, location or hooding of the neo-clitoris
- labiaplasty: adjusting the size or shape of the labia minora or majora
- commisuroplasty: narrowing the superior aspect of the labia majora (the anterior commissure)
- deepening the neo-vagina: occasionally the neo-vagina will not be long enough or will contract in size. This is usually the result of inadequate dilating.

# Masculinizing Surgery (Female-to-Male)

## Surgical procedures

### *FTM chest surgery*

These procedures allow the FTM patient to live more easily in the male gender role, improving psychological and social functioning.<sup>7,48,92</sup> Chest surgery may be the sole surgical step in gender transition.<sup>10</sup>

#### 1. Subcutaneous mastectomy

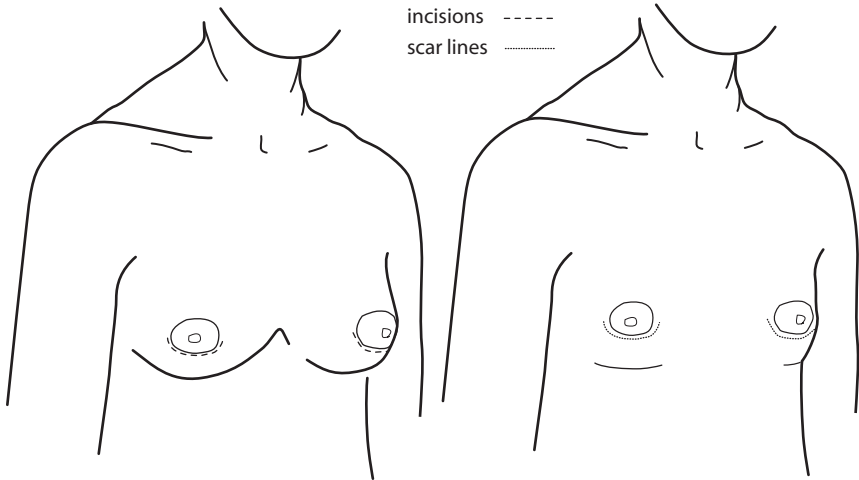
The mastectomy procedure (performed by the plastic surgeon) should achieve more than just a flat chest: ideally, the subcutaneous mastectomy results in a chest which has an aesthetically pleasing male contour, is fully sensate, and has minimal scarring.<sup>48,93,94</sup> The procedure consists of removal of most of the breast tissue, removal of excess skin, and removal of the inframammary fold.<sup>92,93</sup>

Sparing of the nipple and areola is sufficient if the nipple-areolar complex is appropriately sized and shaped, but often reduction and repositioning of the nipple-areolar complex is required to approximate male nipples.<sup>92,93</sup> Revisional surgery is often required.<sup>92</sup>

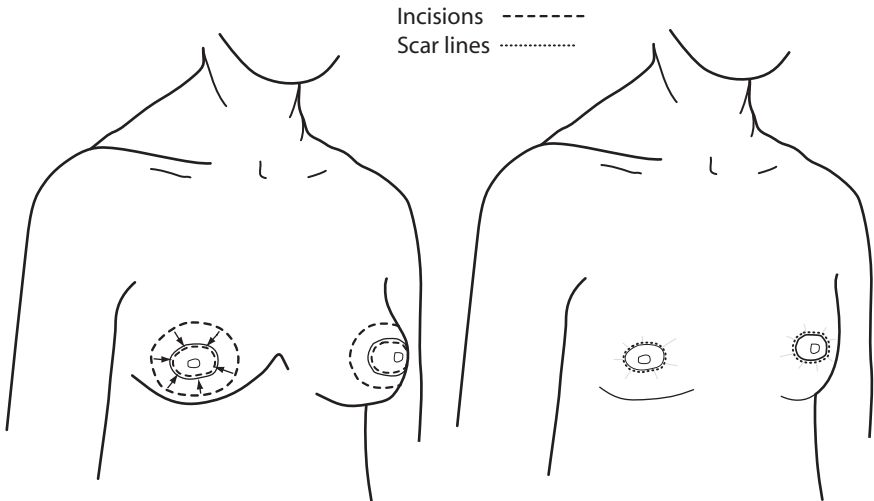
The choice of technique must be appropriately selected for the patient's breast size and skin quality:

- a) Small breasts with good skin elasticity may be removed with a minimum of incisions and subsequent scarring. A periareolar (or "keyhole") approach is most often utilized in these instances.<sup>92,95</sup> The diagram on the next page illustrates this technique.
- b) Moderately sized breasts (B cup) with good skin elasticity can most often be removed with a concentric incision which gathers skin and leaves a scar completely around the areola.<sup>94,96,97</sup> The diagram on the next page illustrates this technique.
- c) Large breasts or moderately-sized breasts with poor elasticity will require more incisions to remove excess skin.<sup>92,95</sup> The diagram on page 17 illustrates this technique.
- d) Very large or pendulous breasts require a full mastectomy (which includes removal of the nipple) with free grafting of the nipple-areolar complex to the appropriate new location.<sup>94,95</sup> This technique will impact nipple sensation significantly but may be the only option for large or inelastic breasts.

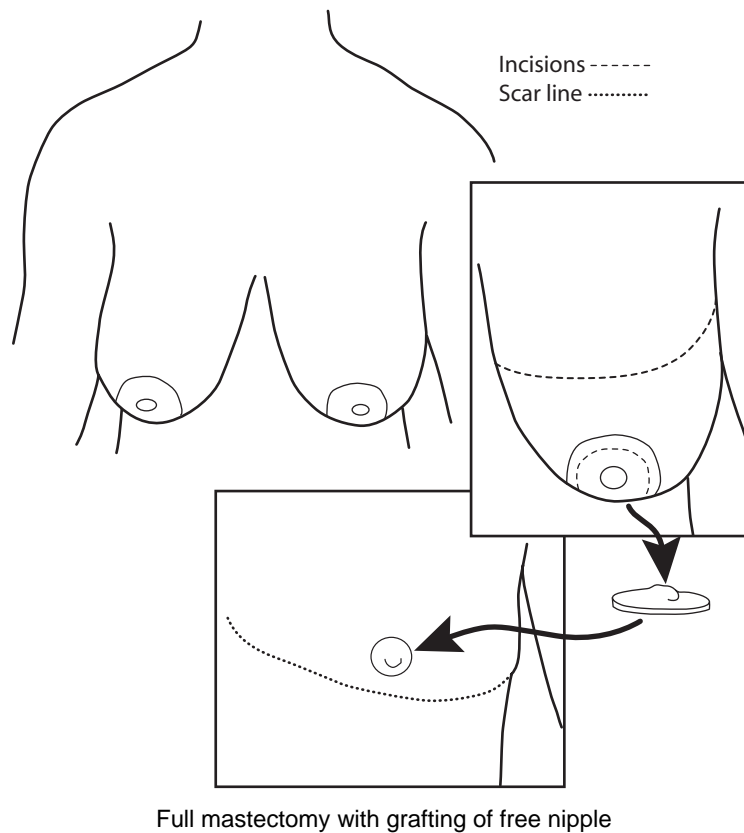
Skin which is inelastic (often due to years of breast binding) can adversely affect the outcome and will influence (and limit) the surgeon's choice of technique.<sup>92</sup>



Keyhole approach for smaller breasts



Concentric incision approach



## 2. Breast reduction

Some patients will choose a breast reduction in lieu of a subcutaneous mastectomy. Prior reduction affects options for reconstruction so should be approached cautiously for the patient who wants a full reconstruction in the future.

### *Hysterectomy and oophorectomy*

Hysterectomy and oophorectomy may be sought to reduce gender dysphoria relating to the presence of these organs, to treat pre-existing gynecological problems, to prevent menstrual bleeding in the patient who cannot tolerate testosterone, or to obviate the necessity for regular Pap testing in the severely dysphoric patient who cannot tolerate vaginal examination (by removal of the cervix in a total hysterectomy). As discussed in *Transgender Primary Medical Care: Suggested Guidelines for Clinicians in British Columbia*,<sup>6</sup> while there are no data on the risks of long-term testosterone use, there are concerns about the potential risk of ovarian and uterine cancer from conversion of testosterone to (unopposed) estrogen, and preventive hysterectomy and oophorectomy are recommended by some endocrinologists. Oophorectomy also allows the reduction of testosterone dosage (and hence associated health risks and side effects).

Hysterectomy and oophorectomy are gynecological procedures which can be performed laparoscopically (minimally invasive surgery).<sup>98-100</sup> Bilateral oophorectomy is typically accompanied by bilateral removal of the fallopian tubes (salpingectomy).

Some patients may have vaginectomy performed concurrent with a vaginal or abdominal hysterectomy. If urethral extension is sought as part of future genital reconstruction

(e.g., phalloplasty) vaginectomy should not be performed, as vaginal mucosa is used to lengthen the urethra.<sup>9,101</sup> Vaginal hysterectomy may be difficult in the FTM patient who has no history of vaginal sexual penetration, particularly if there is vaginal atrophy relating to long-term testosterone administration.<sup>99,100</sup> If the patient intends to pursue phalloplasty, laparoscopic incision is preferred to spare abdominal flaps that may be required for revisions.<sup>48,98</sup>

## *FTM genital reconstruction*

### 1. Vaginectomy and urethral lengthening

These procedures are usually performed by the urologist and are a requisite part of a phalloplasty, but optional in metaidoioplasty (described in the next paragraph). All vaginal mucosa is excised and the levator ani muscles are approximated to help obliterate the previous vaginal cavity. Vaginal mucosa is then typically recruited to lengthen the urethra which will carry urine through the neophallus in a metaidoioplasty or a phalloplasty.<sup>101,102</sup> Alternatives to vaginal mucosa reported in the literature include bladder mucosa grafts and buccal mucosa grafts.<sup>103-106</sup>

### 2. Metaidoioplasty

Metaidoioplasty (sometimes spelled “metaidioplasty” or “metoidioplasty”), a less complex procedure than phalloplasty, results in a small sensate phallus that may allow for urination while standing.<sup>13,107</sup> The hormonally enlarged clitoris (which is analogous to and functions as the glans penis) is released from its surrounding tissues.<sup>108</sup> A flap of skin from the labia minora is then “wrapped around” the stalk to add bulk, resulting in a small phallus which has erogenous sensation.<sup>49</sup> As described in the preceding paragraph, the fixed part of the urethra can be extended and incorporated into the microphallus by recruiting tissue from the vaginal mucosa.<sup>107,108</sup> This will produce a microphallus which can transmit urine to its distal end under the neo-glans.

Since the clitoris is intervened upon to a lesser degree than in phalloplasty, the metaidoioplasty likely results in greater preservation of erogenous sensation than in phalloplasty. However, the microphallus created by metaidoioplasty is typically not large enough for sexual penetration, and does not appear adult in size.<sup>7,49,107</sup> One experienced surgeon estimates the microphallus will be between half the size of the patient’s little finger and the patient’s thumb;<sup>107</sup> another surgeon reports an average of 5.7 cm (range 4-10 cm) for the microphallus created by metaidoioplasty.<sup>108</sup> Despite the limits of size and sexual function, metaidoioplasty is an option for those FTM patients who do not want to undergo the lengthy phalloplasty procedure with its higher rate of complications and donor site morbidity.

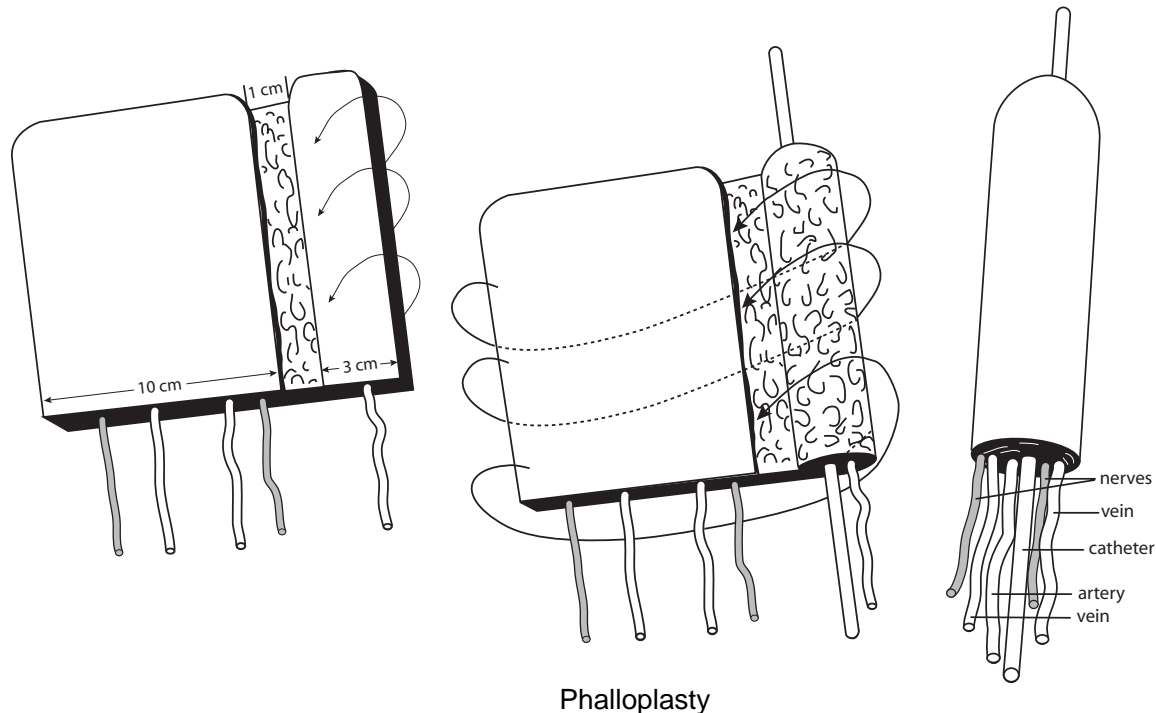
### 3. Phalloplasty

The goals of phalloplasty are:<sup>9,48,109-115</sup>

- creation of a sensate and aesthetically acceptable penis with sufficient length and bulk to be viable for penetrative sexual intercourse (with the aid of a prosthetic erectile device)
- extension of the urethra to the tip of the penis to allow voiding while standing
- preservation of orgasmic capability
- minimal scarring, disfigurement, and functional loss in the donor area

Phalloplasty is a long and complex microsurgical procedure that requires free tissue transfer to create the neophallus.<sup>7,9,49,106,112,116-118</sup> The flap is usually harvested from the forearm,<sup>111,112,119</sup> although use of flaps from the fibula, dorsalis pedis, tensor fasciae latae, groin, deltoid, anterolateral thigh, and lateral arm have also been reported in the literature.<sup>109,111,115,120-122</sup> A small segment of the ulnar forearm is rolled into a tube to form the urethra. This is then rolled within a larger piece of the

forearm (including fat and skin) to form a “tube within a tube”. The procedure results in an adult male-size phallus which transmits urine, and may later achieve rigidity by insertion of an erectile prosthesis. Ideally, the phallus will also carry general and erogenous sensation by coaptation of nerves (including the dorsal nerve of the clitoris) to its base. The native clitoris is not removed but is de-epithelialized and covered by the base of the phallus to preserve erogenous sensation.<sup>7</sup> After anatomic and functional stability is ensured (approximately 1 year), an erectile prosthesis may be placed.<sup>9,97,123,124</sup> Tattooing of the neo-glans may be performed as a later procedure to help create a visible demarcation between the penile shaft and the glans.<sup>7,125</sup>



Differences in male and female anatomy make it more complex to create a de novo phallus in the FTM than to reconstruct a neophallus in the non-transgender male. FTM phalloplasty involves removal of a significant amount of tissue from the forearm and subsequent grafting of this donor site with skin from the thigh.<sup>7,110</sup> In addition, dissection of groin vessels and nerves is necessary, and a vein graft (from the leg) is often required. Thus, multiple surgical sites are produced, all carrying inherent risks for the patient. The procedure produces a large conspicuous scar on the patient's forearm and includes an extended hospital stay (roughly 10 to 14 days). Phalloplasty is an option for those FTM patients who would accept a large donor scar and potential reduction in erogenous sensation in exchange for the construction of a functional adult male phallus.

Second and third stages of phalloplasty may involve placement of a prosthetic stiffener and tattooing of the glans.

#### 4. Scrotoplasty

In a survey of gender clinic FTM patients (n=200), 96% expressed the desire for a scrotum (compared to 52% requesting phalloplasty).<sup>126</sup> A scrotum not only provides aesthetic satisfaction to the patient but also facilitates life in the male role by more closely approximating male appearance in underwear and swim trunks.

Performed by the urologist or plastic surgeon, the scrotoplasty recruits tissue from the labia majora to create a pouch (neo-scrotum) which is appropriately situated over the obliterated introitus.<sup>8,9,108,117,122,127</sup> After stability is ensured, testicular implants may be placed. Although the skin is initially tight, over time the weight of the prosthesis stretches the redraped labial skin to create a more natural appearance.<sup>128</sup>

### *Other masculinizing surgeries*

Various procedures may be performed by the plastic surgeon to reduce stereotypical feminine characteristics and approximate masculine facial features and male habitus. Little has been written about these procedures in transsexuals and it is difficult to find surgeons experienced in their execution. These procedures include, but are not limited to: rhinoplasty; chin/jaw implantation; liposuction to reduce fat in the hips, thighs, and buttocks; and calf or pectoral implantation.<sup>7,9,10,48</sup>

## **Suggested timelines and sequencing**

SRS in the FTM who desires both top and bottom constructive procedures is more complex and involved than in the MTF patient. This is mainly due to the larger number of surgical interventions required to complete the transition.

“Bottom surgery” in particular consists of multiple procedures, usually performed by different surgical teams. Included in these procedures are the hysterectomy and oophorectomy (gynecologist), vaginectomy and lengthening of the fixed part of the urethra (urologist), scrotoplasty (urologist or plastic surgeon), and metaidioplasty (urologist) or phalloplasty (plastic surgeon).

In general, every general anesthesia carries risk for any patient. For this reason, specific procedures are often combined into a single operative setting. Many combinations have been tried, including performing almost all the procedures in a single operative setting.<sup>7</sup> However, this approach has been found to produce increased morbidity for the patient, and as such, the following regimen is commonly utilized.

### **1. Chest surgery (possibly with hysterectomy/oophorectomy)**

The first intervention performed is the subcutaneous mastectomy. The hysterectomy and oophorectomy may be performed (either before or after) within the same operative setting.<sup>8,48</sup> Alternatively, hysterectomy may be performed later if chest surgery is done early in transition (before the one year “real life experience” required for hysterectomy has been completed). Some surgical teams perform hysterectomy/oophorectomy at the same time as genital reconstruction.<sup>7</sup>

### **2. Genital surgery (possibly with hysterectomy/oophorectomy)**

After a minimum of 4 to 6 months the second intervention may be undertaken as long as the HBGDA Guidelines for SRS have also been met. This is the longest operation and typically includes the vaginectomy, urethral lengthening, scrotoplasty, and phalloplasty or metaidioplasty (although some surgical teams prefer to separate genital surgery into two steps, with combined hysterectomy/oophorectomy, vaginectomy, and urethral lengthening performed separate from phalloplasty/metaidioplasty<sup>112,129,130</sup>). If the patient chooses a metaidioplasty, this can usually be performed by a single surgeon and requires less operative time. In the case of a phalloplasty, the urological and plastic surgical teams work simultaneously to minimize the length of the general anesthesia. The choice of a metaidioplasty does not negate a phalloplasty later on.

### 3. Tattooing of glans

Tattooing of the neo-glans may be safely performed 6-8 months following the phalloplasty, before the return of full sensation to the phallus.<sup>7</sup>

### 4. Implant placement

If he chooses, the patient may have testicular implants and, in the case of a phalloplasty, an erectile prosthesis may be placed.<sup>8,97,124</sup> These implants are placed in a single setting, a minimum of one year after the second intervention. This ensures stability of wound healing and functionality.

In general, facial masculinizing surgical procedures may be performed safely 3 months before or after the regimen above, provided there are no complications.

## Expected course and recovery

### *Pre-operative*

Following receipt of letters of recommendation and an initial interview with the surgeon to determine appropriateness of SRS, the FTM patient will meet with the surgical team and a history and physical examination will be performed. It is most helpful if the general practitioner provides a letter reviewing the pertinent past medical history of the patient. A discussion outlining the patient's goals will be undertaken and a timeframe for the various interventions will be established (following the guidelines of the surgical team and the HBGDA *Standards of Care*). The specific procedures will be outlined with the patient, including the expected course and recovery times. Risks and complications will be reviewed.

The effects of smoking on skin quality, wound healing, and vascularity are discussed, where appropriate, and patients are strongly encouraged to stop smoking. This is an absolute requirement if a free flap phalloplasty will be performed in the future.<sup>9</sup> Smoking cessation resources will be identified if desired.

In conjunction with the prescribing physician, masculinizing endocrine therapy is stopped 2 to 4 weeks pre-operatively (depending on the specific medication and its route of administration). Medications affecting the coagulation cascade must be stopped 7-10 days prior to surgery. Prior consultation with an appropriate physician is required in the case of complicating medical factors.

The ulnar side of the arm is usually chosen for the urethral reconstruction as there is less hair growth. In the case of the patient who has particularly hairy forearms (often the result of hormonal therapy), epilation prior to surgery may be necessary to prevent hair growth in the neourethra. Excess hair is believed to promote bacterial colonization and calculus formation<sup>105,111,121,131</sup> and some surgeons therefore require electrolysis to be completed at least 3 months prior to phalloplasty.<sup>104,110</sup> Epilation may also be desired by the patient to reduce hair on skin that will be used to create the shaft of the penis; it is certainly less awkward to have this done before rather than after the phalloplasty procedure.

### *Peri-operative*

#### 1. FTM chest surgery + hysterectomy/oophorectomy

The patient undergoing subcutaneous mastectomy along with hysterectomy and oophorectomy will be admitted the same day as surgery and, in most cases, be discharged home the following day.

Patients will take nothing by mouth (with some exceptions for medications) after midnight the night prior to surgery. While in hospital, patients will have routine monitoring by the nursing and surgical staff and residents. Pain management is usually straightforward, allowing for early discharge home with oral analgesics. Antibiotics are usually prescribed.

## **2. FTM genital reconstruction**

The patient undergoing metoidioplasty is typically admitted the same day as surgery. If urethral lengthening is not simultaneously performed, the patient will in most cases be discharged the following day. The patient who undergoes urethral extension as part of the procedure will have a supra-pubic catheter placed at the time of the operation; this is usually removed during the first week. The patient will remain in hospital until the urologist is satisfied with the patency of the neo-urethra (typically 5-10 days).

In the case of a phalloplasty, patients are admitted the day prior to surgery. They will undergo a "bowel prep" (including phosphosoda and antibiotics) and will take nothing by mouth after midnight. Blood will be drawn and an electrocardiogram will be obtained. Occasionally, a chest x-ray is taken. Patients will undergo pre-operative shaving prior to their surgery. The course in hospital will average 10 to 14 days and the patient will remain on bedrest for most of this time. The phallus will be very closely monitored (every hour for the first 2 days) by the nursing and surgical staff, as any compromise in the vascularity of the phallus may necessitate a prompt return to the O.R. A supra-pubic catheter is placed at the time of the operation and this is usually removed during the first week. The Foley catheter will remain in place for 2 to 3 weeks. Patients will use PCA (patient controlled analgesia) and remain on I.V. blood thinners and antibiotics for 5 days. The skin-grafted forearm will be wrapped under occlusive dressings for 5 days.

### *Post-operative*

#### **1. FTM chest surgery (+/- hysterectomy/oophorectomy)**

Patients who have undergone a subcutaneous mastectomy will continue to wear a tensor bandage around the chest for a period of 1 month. Homecare nursing will be arranged to help empty and monitor drains in the operative sites; the drains will be removed by the plastic surgeon during a clinic visit 3-7 days following surgery. Antibiotics continue until the drains are removed. Steri-strips will be placed along the suture lines. Patients may shower 3 days following surgery. The steri-strips should be gently patted dry and will fall off on their own in 7 to 10 days.

It is normal for incisions to be erythematous, but this erythema should not extend or progress to more than 1 to 2 cm from the incision. It is also normal to see or feel the suture knot at the end of the incision line. These superficial suture knots can be a nuisance; however, they are not a cause for concern. If they work their way to the surface (usually around 3 weeks) they can be clipped free. Bruising and swelling is expected and is not a cause for concern unless there is an unusually large amount of swelling (mass) on one side. Patients are usually comfortable 1 or 2 days following the procedure and often back to their daily routine in 1 to 2 weeks (this is variable). However, strenuous activity should be avoided for 4 weeks.

As discussed in *Transgender Primary Medical Care: Suggested Guidelines for Clinicians in British Columbia*,<sup>6</sup> following chest surgery the FTM patient must still be screened for breast cancer, as all glandular tissue may not be completely removed. The patient should be made aware of this risk and informed of screening recommendations.<sup>92</sup>

## 2. FTM genital reconstruction (+/- hysterectomy/oophorectomy)

The patient will follow-up with the plastic surgeon and urologist frequently in the early post-operative period. Typically, the patient would stay in Vancouver to attend two more clinics (5 to 7 days) after discharge from the hospital. The Foley catheter will be removed in the clinic and antibiotics will continue until this time. Sites to be inspected regularly include the neo-phallus and neo-scrotum; if phalloplasty was performed, the forearm with its split thickness skin graft (STSG), the donor thigh (source of the STSG), and the donor calf (source of the vein graft) should also be examined on a regular basis.

The neo-phallus is inspected for quality of wound healing (dehiscence, infection or hypertrophic scarring), ability to void, and presence of urinary fistulae or stricture (typically a late finding). In the patient who has undergone phalloplasty, vascularity of the neo-phallus (color, temperature, turgor, pulse, capillary refill) will be evaluated, along with quality of wound healing and hand/wrist sensation and function in the donor forearm. The skin graft donor site (thigh) will be dressed with a sheet of gauze which becomes incorporated into the ensuing eschar (scab). It may be gradually trimmed away as it lifts up from its edges over the following 1 to 2 weeks.

Occasionally, an arterial-venous fistula (AVF) is created within the neo-phallus during phalloplasty. This is a connection, intentionally made, between the main artery and vein. A palpable "thrill" (vibration) will be present at the distal end of the neo-phallus. AVFs may close on their own or alternatively are disconnected in a minor procedure performed in the clinic several weeks after the phalloplasty.

## Risks and complications

General risks related to operative procedures include deep vein thrombosis, pulmonary embolism, and death. Obviously, these are very serious complications and surgeons, anesthesiologists and nurses take various measures to reduce associated risk. These include I.V. hydration, active monitoring, the use of compression stockings and/or pneumatic compression devices, judicious anticoagulation, and early mobilization. Once home, patients should stay well-hydrated and should not remain in bed for extended periods. Tender, warm, or swollen legs; chest pain; or continued dizzy spells should be investigated in the E.R. If a patient experiences sudden shortness of breath, emergency medical assistance should be sought.

Risks and complications specific to each surgical masculinization procedure (or group of procedures commonly performed together) are discussed below.

### 1. Subcutaneous mastectomy/breast reduction

Risks associated with subcutaneous mastectomy/breast reduction include infection, post-operative bleeding/hematoma, seroma, mastectomy flap necrosis, nipple necrosis (loss of nipple), contour abnormalities, and nipple asymmetry.<sup>92</sup> Scar management (including massage and sun avoidance) will be discussed with the patient; hypertrophic scarring is possible due to intrinsic or extrinsic factors. Decreased sensation to the chest wall and nipple-areola complex is common and usually resolves spontaneously within a few months.<sup>92</sup> Patients who have undergone the free nipple graft technique (larger breasts) initially will have insensate nipples, which may or may not regain some degree of sensation.

Management of complications relating to chest surgery is discussed in Table 4 on the following page.

**Table 4: Management of complications following FTM chest surgery**

Complication	Signs and symptoms	Treatment
Post-operative bleeding/hematoma	expanding painful mass on one side of the chest wall, often with increased bloody output in the drain	<ul style="list-style-type: none"> <li>evacuation in the O.R.</li> </ul>
Infection	progressive pain and blanching erythema which spreads beyond the incisional margins, combined with fever, malaise and leukocytosis	<ul style="list-style-type: none"> <li>small infections: course of antibiotics</li> <li>abscesses: often need to be drained in the O.R. or under ultrasonic guidance</li> <li>persistent infections (caused by multidrug-resistant organisms): consult surgeon</li> </ul>
Seroma	similar to hematoma, but usually after drain has been removed	<ul style="list-style-type: none"> <li>aspiration (1 or more times) by GP or surgeon</li> </ul>
Wound healing problems	most often small dehiscences due to stitch rupture or minor infection	<ul style="list-style-type: none"> <li>if minor, treat with basic wound care: dressing changes, antibiotic ointment</li> <li>if incision line is progressively opening such that the wound is gaping, contact the surgeon</li> </ul>
Mastectomy flap necrosis	usually presents early with non-blanching erythema or mottling of the skin, which progressively becomes darker and non-viable	<ul style="list-style-type: none"> <li>small necrotic areas: basic wound care (dressing changes)</li> <li>larger areas of flap loss: follow and dress regularly; may require grafting at later date</li> </ul>
Nipple necrosis (loss of nipple)	typically presents early with progressive duskiness (darkening) of the nipple and areola, or absence of capillary refill; if free nipple graft, loss would not be detected until post-operative day #5 when occlusive dressings are taken down by the surgeon	<ul style="list-style-type: none"> <li>immediate post-operative period (within hours): attempt to save nipple by loosening dressings or removing stitches; if unsuccessful, surgeon may remove nipple and replace as free graft</li> <li>if not detected immediately, the non-viable nipple would likely need to be debrided, with future nipple reconstruction using local flaps or tattooing techniques</li> </ul>
Contour abnormalities	asymmetrical appearance after resolution of post-operative swelling (8-12 weeks)	<ul style="list-style-type: none"> <li>major asymmetries may be addressed with revisional liposuction</li> </ul>
Nipple asymmetry	asymmetrical size or location of nipples after resolution of post-operative swelling (at least 3 months following surgery)	<ul style="list-style-type: none"> <li>revisional surgery</li> </ul>
Hypertrophic scarring		<ul style="list-style-type: none"> <li>prevention: sun avoidance, massage</li> <li>severe scarring may require surgical revision</li> </ul>

## 2. Hysterectomy/oophorectomy

This is a routine gynecologic procedure. Complications/risks are no different in the female-to-male patient than the non-transgender female patient.

## 3. FTM genital reconstruction

Risks associated with FTM genital reconstruction regardless of procedure include infection, post-operative bleeding/hematoma, seroma, and hypertrophic scar formation. Laceration of the rectum is an uncommon complication of vaginectomy or vaginal hysterectomy.<sup>132</sup> Urethral fistula or stricture is common following urethral lengthening and anastomosis (in either metaidioplasty or phalloplasty).<sup>7,49,103,105,106,111,131</sup> Additional risks of phalloplasty include partial or complete flap necrosis, compromised sensation/function of the hand and wrist of the donor arm, and dissatisfaction with the size/shape of the neophallus or the aesthetic appearance of donor sites.<sup>7-9,48,49,107,128,129,131</sup> The poor aesthetic result of the donor forearm is one of the disadvantages of the current phalloplasty method.<sup>109,117</sup> Implant extrusion, infection, or failure may occur after scrotoplasty or penile prosthetic placement.<sup>97,111,118,124,128,133-135</sup>

Decreased sensation at all sites is common and usually resolves spontaneously within a few weeks to months. Following phalloplasty the neophallus will be insensate for the first several months, with sensation gradually progressing from base to tip throughout the following year. Decreased sensation in the grafted forearm may be significant, but usually improves over time as small nerves branch into the skin graft; however, sensation will never fully return. Decreased erogenous sensation is a potential risk of metoidioplasty and phalloplasty,<sup>130</sup> but sexual satisfaction can remain even in the presence of decreased tactile and erogenous sensation, and orgasmic capability is reported by most patients.<sup>89,117,131,135</sup>

Partial flap (phallus) necrosis occurs occasionally, most often in the early post-operative phase. By the time the patient is discharged home he will have undergone skin grafting, or will be undergoing a wound care regimen appropriate for the circumstance. Complete flap loss is a devastating complication which, fortunately, is a rare occurrence. Again, vascular compromise of the flap would most likely occur in the early post-operative period. By the time the patient is discharged home the risk of total flap failure is quite low.

Management of complications relating to FTM genital reconstruction is discussed in the table below (continuing on the following page).

**Table 5: Management of complications following FTM genital reconstruction**

Complication	Signs and symptoms	Treatment
Post-operative bleeding/hematoma (all sites)	usually presents with ongoing bleeding and swelling of the phallus or donor forearm while patient is still in hospital; intra-abdominal (or retro-peritoneal) hematomas also may occur in the early post-operative period	<ul style="list-style-type: none"> <li>evacuation in the O.R.</li> </ul>
Infection (all sites)	progressive pain and blanching erythema which spreads beyond the incisional margins, combined with fever, malaise and leukocytosis	<ul style="list-style-type: none"> <li>small infections: course of antibiotics</li> <li>abscesses: often need to be drained in the O.R. or under ultrasonic guidance</li> <li>persistent infections (caused by multidrug-resistant organisms): consult surgeon</li> </ul>
Seroma (recipient site)	must be differentiated from urinary fistula (by surgeon)	<ul style="list-style-type: none"> <li>aspiration by the surgeon</li> </ul>
Wound healing problems (all sites)	most often small dehiscences due to stitch rupture or minor infection	<ul style="list-style-type: none"> <li>if minor, treat with basic wound care: dressing changes, antibiotic ointment</li> <li>if incision line is progressively opening such that the wound is gaping, contact the surgeon</li> </ul>
Partial or complete flap necrosis (loss of phallus)	usually presents early with non-blanching erythema or mottling of the skin, which progressively becomes darker and non-viable	<ul style="list-style-type: none"> <li>unusual to happen after discharge from hospital</li> <li>immediate contact with surgeon is required</li> </ul>
Compromised sensation/function of hand and wrist (donor arm)	compromised hand or wrist function is common after phalloplasty but typically resolves within a few weeks; permanent numbness in the hand or wrist of the donor forearm is rare	<ul style="list-style-type: none"> <li>~5% of patients require prolonged physiotherapy to recover fully</li> </ul>
Urethral fistula	urine flow from location other than urethral opening (occurs in up to 45% of phalloplasties)	<ul style="list-style-type: none"> <li>surgeon should be notified and the fistula should be monitored and kept clean</li> <li>most are self-resolving; a fistula which does not resolve within 2-3 weeks will likely require revisional surgery by a urologist</li> </ul>

*continued on following page*

Complication	Signs and symptoms	Treatment
Urethral stricture	progressive inability to void; may be accompanied by fistulae	<ul style="list-style-type: none"> <li>dilation by urologist under local anesthesia</li> <li>deep stricture (at junction of native and neo-urethra) may require revision in the O.R.</li> </ul>
Implant infection, extrusion, or failure	<ul style="list-style-type: none"> <li>infection: increased warmth or drainage from the incisions following implantation</li> <li>extrusion: visible extrusion of testicular prostheses or erectile prosthesis</li> <li>rupture/failure: inflammation, change in size/shape; diagnosis confirmed clinically</li> </ul>	<ul style="list-style-type: none"> <li>surgical removal with later replacement</li> </ul>
Mechanical failure of hydraulic erectile prosthesis	<ul style="list-style-type: none"> <li>erectile dysfunction</li> </ul>	<ul style="list-style-type: none"> <li>mechanical repair, or surgical removal with later replacement</li> </ul>
Hypertrophic scarring (all sites)		<ul style="list-style-type: none"> <li>severe scarring may require surgical revision</li> </ul>

## Revisional surgery

Performing an aesthetically pleasing subcutaneous mastectomy in the biological female who desires a male chest can be a challenging operation. It differs from mastectomy for breast disease (or as a prophylactic measure) since the goals are very different: the aim of chest surgery in the FTM is not just to remove all of the breast tissue, but also to recontour the chest to create a masculine appearance.<sup>94</sup> The procedure is also usually more difficult than a gynecomastia correction since the FTM transsexual often has considerably more breast volume and a greater degree of ptosis (natural droop) to contend with. Moreover, the common practice of “breast binding” severely impacts the quality of breast skin,<sup>93</sup> which is a major factor in choosing the correct surgical procedure. As such, subcutaneous mastectomy in the FTM patient has a fairly high rate of revisional surgery associated with it (33-45%).<sup>136</sup>

Patients with larger breasts or poor skin quality have a higher chance of requiring revisional surgery. Typical revisions include, but are not limited to:<sup>137</sup>

- liposuction to improve contour abnormalities
- scar revisions
- excision of skin excess, wrinkling or puckering
- adjustment of nipple-areola complex position or size

Revisional surgery after phalloplasty is less common as an isolated procedure. However, since many patients choose to have testicular implants and/or erectile prostheses placed later, it is simple to perform minor “touch-ups” (e.g. revision of the coronal rim) at the same time. Revisions may also be necessary to correct urinary dysfunction, a common complication of urethral lengthening.

## Conclusion

The primary care provider plays an important role in preparation of the patient for surgery and in evaluation following discharge from hospital. While minor complications after routine procedures can typically be managed by the trans-experienced primary care provider, due to the unique and complex nature of SRS, consultation with the original surgeon is advised whenever there are concerns about care.

## References

1. Lawrence, A. A. (2003). Factors associated with satisfaction or regret following male-to-female sex reassignment surgery. *Archives of Sexual Behavior, 32*, 299-315.
2. Michel, A., Anseau, M., Legros, J. J., Pitchot, W., & Mormont, C. (2002). The transsexual: what about the future? *European Psychiatry, 17*, 353-362.
3. Pfäfflin, F., & Junge, A. (1998). *Sex reassignment – Thirty years of international follow-up studies; SRS: A comprehensive review, 1961-1991* (R. B. Jacobson & A. B. Meier, Trans.). Düsseldorf, Germany: Symposion Publishing. (Original work published 1992.)
4. Mate-Kole, C., Freschi, M., & Robin, A. (1990). A controlled study of psychological and social changes after surgical gender reassignment in selected male transsexuals. *British Journal of Psychiatry, 157*, 261-264.
5. Pfäfflin, F. (1992). Regrets after sex reassignment surgery. In W. O. Bockting & E. Coleman (Eds.), *Gender dysphoria: Interdisciplinary approaches in clinical management* (pp. 69-85). Binghamton, NY: Haworth Press.
6. Feldman, J., & Goldberg, J. M. (2006). *Transgender primary medical care: Suggested guidelines for clinicians in British Columbia*. Vancouver, BC: Vancouver Coastal Health Authority.
7. Monstrey, S., Hoebeke, P., Dhont, M., De Cuypere, G., Rubens, R., Moerman, M., Hamdi, M., Van Landuyt, K., & Blondeel, P. (2001). Surgical therapy in transsexual patients: a multi-disciplinary approach. *Acta Chirurgica Belgica, 101*, 200-209.
8. Greenwald, D. & Stadelmann, W. (2001). Gender reassignment. *eMedicine Journal, 2*. Retrieved January 1, 2005, from <http://www.emedicine.com/plastic/topic434.htm>.
9. Chesson, R. R., Gilbert, D. A., Jordan, G. H., Schlossberg, S. M., Ramsey, G. T., & Gilbert, D. M. (1996). The role of colpocleisis with urethral lengthening in transsexual phalloplasty. *American Journal of Obstetrics and Gynecology, 175*, 1443-1449.
10. Meyer, W. J., III, Bockting, W. O., Cohen-Kettenis, P. T., Coleman, E., Di Ceglie, D., Devor, H., Gooren, L., Hage, J. J., Kirk, S., Kuiper, B., Laub, D., Lawrence, A., Menard, Y., Monstrey, S., Patton, J., Schaefer, L., Webb, A., & Wheeler, C. C. (2001). *The standards of care for Gender Identity Disorders* (6<sup>th</sup> ed.). Minneapolis, MN: Harry Benjamin International Gender Dysphoria Association.
11. Bockting, W. O., Knudson, G., & Goldberg, J. M. (2006). *Counselling and mental health care of transgender adults and loved ones*. Vancouver, BC: Vancouver Coastal Health Authority.
12. Kirk, S. (1999). Guidelines for selecting HIV positive patients for genital reconstructive surgery. *International Journal of Transgenderism, 3*(1+2). Retrieved January 1, 2005, from [http://www.symposion.com/ijt/hiv\\_risk/kirk.htm](http://www.symposion.com/ijt/hiv_risk/kirk.htm).
13. Israel, G. E., & Tarver, D. E. I., II. (1997). *Transgender care: Recommended guidelines, practical information, and personal accounts*. Philadelphia, PA: Temple University Press.
14. White Holman, C., & Goldberg, J. M. (2006). *Social and medical advocacy with transgender people and loved ones: Recommendations for BC clinicians* Vancouver, BC, Canada: Vancouver Coastal Health Authority.
15. Rubinstein, L. M., Benjamin, L., & Kleinkopf, V. (1979). Menstrual patterns and women's attitudes following sterilization by Falope rings. *Fertility and Sterility, 31*, 641-646.
16. Rosenfeld, B. L., Taskin, O., Kafkashli, A., Rosenfeld, M. L., & Chuong, C. J. (1998). Sequelae of postpartum sterilization. *Archives of Gynecology and Obstetrics, 261*, 183-187.

17. Vemer, H. M., Colla, P., Schoot, B. C., Willemsen, W. N., Bierkens, P. B., & Rolland, R. (1986). Regret after sterilization in women. *Nederlands Tijdschrift voor Geneeskunde*, 130, 410-413.
18. Miller, W. B., Shain, R. N., & Pasta, D. J. (1991). The pre- and poststerilization predictors of poststerilization regret in husbands and wives. *Journal of Nervous and Mental Disease*, 179, 602-608.
19. Jamieson, D. J., Kaufman, S. C., Costello, C., Hillis, S. D., Marchbanks, P. A., & Peterson, H. B. (2002). A comparison of women's regret after vasectomy versus tubal sterilization. *Obstetrics & Gynecology*, 99, 1073-1079.
20. Taucher, S., Gnant, M., & Jakesz, R. (2003). Preventive mastectomy in patients at breast cancer risk due to genetic alterations in the BRCA1 and BRCA2 gene. *Langenbecks Archives of Surgery*, 388, 3-8.
21. Anderson, B. O. (2001). Prophylactic surgery to reduce breast cancer risk: A brief literature review. *The Breast Journal*, 7, 321-330.
22. Borgen, P. I., Hill, A. D., Tran, K. N., Van Zee, K. J., Massie, M. J., Payne, D. et al. (1998). Patient regrets after bilateral prophylactic mastectomy. *Annals of Surgical Oncology*, 5, 603-606.
23. Montgomery, L. L., Tran, K. N., Heelan, M. C., Van Zee, K. J., Massie, M. J., Payne, D. K. et al. (1999). Issues of regret in women with contralateral prophylactic mastectomies. *Annals of Surgical Oncology*, 6, 546-552.
24. Payne, D. K., Biggs, C., Tran, K. N., Borgen, P. I., & Massie, M. J. (2000). Women's regrets after bilateral prophylactic mastectomy. *Annals of Surgical Oncology*, 7, 150-154.
25. Lantz, P. M., Janz, N. K., Fagerlin, A., Schwartz, K., Liu, L., Lakhani, I., Salem, B., & Katz, S. J. (2005). Satisfaction with surgery outcomes and the decision process in a population-based sample of women with breast cancer. *Health Services Research*, 40, 745-767.
26. Harcourt, D., & Rumsey, N. (2001). Psychological aspects of breast reconstruction: a review of the literature. *Journal of Advanced Nursing*, 35, 477-487.
27. Coon, S. K., Burris, R., Coleman, E. A., & Lemon, S. J. (2002). An analysis of telephone interview data collected in 1992 from 820 women who reported problems with their breast implants to the food and drug administration. *Plastic and Reconstructive Surgery*, 109, 2043-2051.
28. Roberts, C. S., Wells, K. E., & Walden, K. (1999). Toward understanding women who request removal of silicone breast implants. *Breast Journal*, 5, 246.
29. Tweed, A. (2003). *Health care utilization among women who have undergone breast implant surgery*. Vancouver, BC: British Columbia Centre of Excellence in Women's Health.
30. Elit, L., Esplen, M. J., Butler, K., & Narod, S. (2001). Quality of life and psychosexual adjustment after prophylactic oophorectomy for a family history of ovarian cancer. *Familial Cancer*, 1, 149-156.
31. Clark, J. A., Wray, N. P., & Ashton, C. M. (2001). Living with treatment decisions: Regrets and quality of life among men treated for metastatic prostate cancer. *Journal of Clinical Oncology*, 19, 72-80.
32. Eiser, C., Darlington, A.-S. E., Stride, C. B., & Grimer, R. (2001). Quality of life implications as a consequence of surgery: limb salvage, primary and secondary amputation. *Sarcoma*, 5, 189-195.
33. Victorzon, M. & Tolonen, P. (2001). Bariatric Analysis and Reporting Outcome System (BAROS) following laparoscopic adjustable gastric banding in Finland. *Obesity Surgery*, 11, 740-743.
34. Wheeler, T. L., II., Richter, H. E., Varner, R. E., Burgio, K. L., Redden, D. T., Goode, P. S., & Chen, C. G. (2005). *Regret, satisfaction and symptom improvement: Analysis of the impact of colpopoiesis for the management of severe pelvic organ prolapse*. Poster presented at the 31<sup>st</sup> Annual Scientific Meeting of the Society of Gynecologic Surgeons, Rancho Mirage, CA.

35. Landen, M., Walinder, J., Hambert, G., & Lundstrom, B. (1998). Factors predictive of regret in sex reassignment. *Acta Psychiatrica Scandinavica*, *97*, 284-289.
36. Cohen-Kettenis, P. T., & Van Goozen, S. H. M. (1997). Sex reassignment of adolescent transsexuals: a follow-up study. *Journal of the American Academy of Child and Adolescent Psychiatry*, *36*, 263-271.
37. Smith, Y. L. S., Van Goozen, S. H. M., Kuiper, A. J., & Cohen-Kettenis, P. T. (2005). Sex reassignment: Outcomes and predictors of treatment for adolescent and adult transsexuals. *Psychological Medicine*, *35*, 89-99.
38. Rakic, Z., Starcevic, V., Maric, J., & Kelin, K. (1996). The outcome of sex reassignment surgery in Belgrade: 32 patients of both sexes. *Archives of Sexual Behavior*, *25*, 515-525.
39. Rehman, J., Lazer, S., Benet, A. E., Schaefer, L. C., & Melman, A. (1999). The reported sex and surgery satisfactions of 28 postoperative male-to-female transsexual patients. *Archives of Sexual Behavior*, *28*, 71-89.
40. Kuiper, A. J. & Cohen-Kettenis, P. T. (1998). Gender role reversal among postoperative transsexuals. *International Journal of Transgenderism*, *2*(3). Retrieved January 1, 2005, from <http://www.symposion.com/ijt/ijtc0502.htm>.
41. Kanhai, R. C. J., Hage, J. J., Asscheman, H., & Mulder, J. W. (1999). Augmentation mammoplasty in male-to-female transsexuals. *Plastic and Reconstructive Surgery*, *104*, 542-549.
42. Dahl, M., Feldman, J., Goldberg, J. M., Jaber, A., Bockting, W. O., & Knudson, G. (2006). *Endocrine therapy for transgender adults in British Columbia: Suggested guidelines*. Vancouver, BC: Vancouver Coastal Health Authority.
43. Schrang, E. A. (1997). Genital reassignment surgery: A source of happiness for my patients. In G. E. Israel & D. E. I. Tarver, II. (Eds.), *Transgender care: Recommended guidelines, practical information and personal accounts* (pp. 236-240). Philadelphia, PA: Temple University Press.
44. Karim, R. B., Hage, J. J., & Mulder, J. W. (1996). Neovaginoplasty in male transsexuals: Review of surgical techniques and recommendations regarding eligibility. *Annals of Plastic Surgery*, *37*, 669-675.
45. Krege, S., Bex, A., Lummen, G., & Rubben, H. (2001). Male-to-female transsexualism: a technique, results and long-term follow-up in 66 patients. *BJU International*, *88*, 396-402.
46. Laub, D. R., Laub, D. R., II., & Biber, S. (1988). Vaginoplasty for gender confirmation. *Clinics in Plastic Surgery*, *15*, 463-470.
47. Perovic, S. V., Stanojevic, D. S., & Djordjevic, M. L. (2000). Vaginoplasty in male transsexuals using penile skin and a urethral flap. *BJU International*, *86*, 843-850.
48. Hage, J. J. (1995). Medical requirements and consequences of sex reassignment surgery. *Medicine, Science and the Law*, *35*, 17-24.
49. Takata, L. L., & Meltzer, T. R. (2000). Procedures, postoperative care, and potential complications of gender reassignment surgery for the primary care physician. *Primary Psychiatry*, *7*, 74-78.
50. Eldh, J. (1993). Construction of a neovagina with preservation of the glans penis as a clitoris in male transsexuals. *Plastic and Reconstructive Surgery*, *91*, 895-900.
51. Kim, S. K., Park, H. H., Lee, K. C., Park, J. M., Kim, J. T., & Kim, M. C. (2003). Long-term results in patients after rectosigmoid vaginoplasty. *Plastic and Reconstructive Surgery*, *112*, 143-151.
52. Lenaghan, R., Wilson, N., Lucas, C. E., & Ledgerwood, A. M. (1997). The role of rectosigmoid neocolporrhaphy. *Surgery*, *122*, 856-860.

53. Maas, S. M., Eijsbouts, Q. A., Hage, J. J., & Cuesta, M. A. (1999). Laparoscopic rectosigmoid colpopoiesis: does it benefit our transsexual patients? *Plastic and Reconstructive Surgery*, *103*, 518-524.
54. Rubin, S. O. (1993). Sex-reassignment surgery male-to-female. Review, own results and report of a new technique using the glans penis as a pseudoclititoris. *Scandinavian Journal of Urology and Nephrology Supplementum*, *154*, 1-28.
55. Rehman, J., & Melman, A. (1999). Formation of neoclititoris from glans penis by reduction glansplasty with preservation of neurovascular bundle in male-to-female gender surgery: functional and cosmetic outcome. *Journal of Urology*, *161*, 200-206.
56. Tiewtranon, P., Chokerungvaranon, P., Jindarak, S., & Wannachamras, S. (2001). *Sensate pedicled neoclititoris in the neovaginoplasty for 250 male transsexuals*. Paper presented at the 17<sup>th</sup> Biennial Symposium of the Harry Benjamin Gender Dysphoria Association, Galveston, TX.
57. Giraldo, F., Esteva, I., Bergero, T., Cano, G., Gonzalez, C., Salinas, P., Rivada, E., Lara, J. S., & Soriguer, F. (2004). Corona glans clitoroplasty and urethropreputial vestibuloplasty in male-to-female transsexuals: the vulval aesthetic refinement by the Andalusia Gender Team. *Plastic and Reconstructive Surgery*, *114*, 1543-1550.
58. Herzog, M. E., & Santucci, R. A. (2002). Incisionless in-office castration using a veterinary castration device (Burdizzo clamp). *Urology*, *59*, 946.
59. Reid, R. W. (1996). *Orchidectomy as a first stage towards gender reassignment: A positive option*. Paper presented at Gendys '96: The Fourth International Gender Dysphoria Conference, Manchester, England.
60. Ousterhout, D. K. (1987). Feminization of the forehead: contour changing to improve female aesthetics. *Plastic and Reconstructive Surgery*, *79*, 701-713.
61. Ousterhout, D. K. (2003). *Feminization of the transsexual (except for SRS)*. San Francisco: Author.
62. Ousterhout, D. K. (1997). Facial surgery for the transsexual. In G. E. Israel & D. E. I. Tarver, II. (Eds.), *Transgender care: Recommended guidelines, practical information and personal accounts* (pp. 225-228). Philadelphia, PA: Temple University Press.
63. Becking, A. G., Tuinzing, D. B., Hage, J. J., & Gooren, L. J. G. (1996). Facial corrections in male to female transsexuals: a preliminary report on 16 patients. *Journal of Oral and Maxillofacial Surgery*, *54*, 413-418.
64. Hage, J. J., Vossen, M., & Becking, A. G. (1997). Rhinoplasty as part of gender-confirming surgery in male transsexuals: basic considerations and clinical experience. *Annals of Plastic Surgery*, *39*, 266-271.
65. Conrad, K., & Yoskovitch, A. (2003). Endoscopically facilitated reduction laryngochoondroplasty. *Archives of Facial Plastic Surgery*, *5*, 345-348.
66. Wolfort, F. G., Dejerine, E. S., Ramos, D. J., & Parry, R. G. (1990). Chondrolaryngoplasty for appearance. *Plastic and Reconstructive Surgery*, *86*, 464-469.
67. Isshiki, N., Taira, T., & Tanabe, M. (1983). Surgical alteration of the vocal pitch. *Journal of Otolaryngology*, *12*, 335-340.
68. Donald, P. J. (1982). Voice change surgery in the transsexual. *Head and Neck Surgery*, *4*, 433-437.
69. Oates, J. M., & Dacakis, G. (1997). Voice change in transsexuals. *Venereology: Interdisciplinary, International Journal of Sexual Health*, *10*, 178-187.
70. Brown, M., Perry, A., Cheesman, A. D., & Pring, T. (2000). Pitch change in male-to-female transsexuals: has phonosurgery a role to play? *International Journal of Language and Communication Disorders*, *35*, 129-136.

71. Kunachak, S., Prakunhungsit, S., & Sujjalak, K. (2000). Thyroid cartilage and vocal fold reduction: a new phonosurgical method for male-to-female transsexuals. *Annals of Otolaryngology, Rhinology and Laryngology*, 109, 1082-1086.
72. Neumann, K., Welzel, C., Gonnermann, U., & Wolfradt, U. (2002). Cricothyroidopexy in male-to-female transsexuals: Modification Type IV. *International Journal of Transgenderism*, 6(3). Retrieved January 1, 2005, from [http://www.symposion.com/ijtvo06no03\\_03.htm](http://www.symposion.com/ijtvo06no03_03.htm).
73. Neumann, K., Welzel, C., Gonnermann, U., & Wolfradt, U. (2002). Satisfaction of MtF transsexuals with operative voice therapy: A Questionnaire-based preliminary study. *International Journal of Transgenderism*, 6(4). Retrieved January 1, 2005, from [http://www.symposion.com/ijtvo06no04\\_02.htm](http://www.symposion.com/ijtvo06no04_02.htm)
74. Yang, C. Y., Palmer, A. D., Murray, K. D., Meltzer, T. R., & Cohen, J. I. (2002). Cricothyroid approximation to elevate vocal pitch in male-to-female transsexuals: Results of surgery. *Annals of Otolaryngology, Rhinology and Laryngology*, 111, 477-485.
75. Wagner, I., Fugain, C., Monneron-Girard, L., Cordier, B., & Chabolle, F. (2003). Pitch-raising surgery in fourteen male-to-female transsexuals. *Laryngoscope*, 113, 1157-1165.
76. Davies, S., & Goldberg, J. M. (2006). *Transgender speech feminization/masculinization: Suggested guidelines for BC clinicians*. Vancouver, BC: Vancouver Coastal Health Authority.
77. Schmid, A., Tzur, A., Leshko, L., & Krieger, B. P. (2005). Silicone embolism syndrome: a case report, review of the literature, and comparison with fat embolism syndrome. *Chest*, 127, 2276-2281.
78. Chastre, J., Basset, F., Viau, F., Dournovo, P., Bouchama, A., Akesbi, A., & Gilbert, C. (1983). Acute pneumonitis after subcutaneous injections of silicone in transsexual men. *New England Journal of Medicine*, 308, 764-767.
79. Coulaud, J. M., Labrousse, J., Carli, P., Galliot, M., Vilde, F., & Lissac, J. (1983). Adult respiratory distress syndrome and silicone injection. *Toxicological European Research / Recherche Européenne en Toxicologie*, 5, 171-174.
80. Duong, T., Schonfeld, A. J., Yungbluth, M., & Slotten, R. (1998). Acute pneumopathy in a nonsurgical transsexual. *Chest*, 113, 1127-1129.
81. Fox, L. P., Geyer, A. S., Husain, S., Ia-Latta, P., & Grossman, M. E. (2004). Mycobacterium abscessus cellulitis and multifocal abscesses of the breasts in a transsexual from illicit intramammary injections of silicone. *Journal of the American Academy of Dermatology*, 50, 450-454.
82. Gaber, Y. (2004). Secondary lymphoedema of the lower leg as an unusual side-effect of a liquid silicone injection in the hips and buttocks. *Dermatology*, 208, 342-344.
83. Farina, L. A., Palacio, V., Salles, M., Fernandez-Villanueva, D., Vidal, B., & Menendez, P. (1997). Scrotal granuloma caused by oil migrating from the hip in 2 transsexual males (scrotal sclerosing lipogranuloma). *Archivos Espanoles de Urologia*, 50, 51-53.
84. Ratnam, S. S., & Lim, S. M. (1982). Augmentation mammoplasty for the male transsexual. *Singapore Medical Journal*, 23, 107-109.
85. Leslie, K., Buscombe, J., & Davenport, A. (2000). Implant infection in a transsexual with renal failure. *Nephrology Dialysis Transplantation*, 15, 436-437.
86. Crichton, D. (1993). Gender reassignment surgery for male primary transsexuals. *South African Medical Journal*, 83, 347-349.
87. Liguori, G., Trombetta, C., Buttazzi, L., & Belgrano, E. (2001). Acute peritonitis due to introital stenosis and perforation of a bowel neovagina in a transsexual. *Obstetrics and Gynecology*, 97, 828-829.

88. Lawrence, A. A. (2005). Sexuality before and after male-to-female sex reassignment surgery. *Archives of Sexual Behavior*, 34, 147-166.
89. Lief, H. I. & Hubschman, L. (1993). Orgasm in the postoperative transsexual. *Archives of Sexual Behavior*, 22, 145-155.
90. Meltzer, T. R. (2001). *Aesthetic refinements to the secondary labioplasty*. Paper presented at the 17<sup>th</sup> Biennial Symposium of the Harry Benjamin Gender Dysphoria Association, Galveston, TX.
91. Wilson, N. (2002). The aesthetic vulva: Perineal cosmesis in the male-to-female transsexual. *International Journal of Transgenderism*, 6(4). Retrieved January 1, 2005, from [http://www.symposion.com/ijt/ijtvo06no04\\_01.htm](http://www.symposion.com/ijt/ijtvo06no04_01.htm).
92. Hage, J. J., & Bloem, J. J. A. M. (1995). Chest wall contouring for female-to-male transsexuals: Amsterdam experience. *Annals of Plastic Surgery*, 34, 59-66.
93. Hage, J. J., & van Kesteren, P. J. (1995). Chest-wall contouring in female-to-male transsexuals: basic considerations and review of the literature. *Plastic and Reconstructive Surgery*, 96, 386-391.
94. Gilbert, D. A., & Gilbert, D. M. (n.d.). Chest contouring in the female transgender patient. Unpublished manuscript.
95. Monstrey, S., Selvaggi, G., Van Landuyt, K., Blondeel, P., Hamdi, M., & Hoebeke, P. (2001). *Subcutaneous mastectomy in female-to-male transsexuals*. Paper presented at the 17<sup>th</sup> Biennial Symposium of the Harry Benjamin Gender Dysphoria Association, Galveston, TX.
96. Colic, M. M., & Colic, M. M. (2005). Circumareolar mastectomy in female-to-male transsexuals and large gynecomastias: A personal approach. *Aesthetic Plastic Surgery*, 24, 454.
97. Hoebeke, P., De Cuypere, G., Ceulemans, P., & Monstrey, S. (2003). Obtaining rigidity in total phalloplasty: experience with 35 patients. *Journal of Urology*, 169, 221-223.
98. Ergeneli, M. H., Duran, E. H., Ozcan, G., & Erdogan, M. (1999). Vaginectomy and laparoscopically assisted vaginal hysterectomy as adjunctive surgery for female-to-male transsexual reassignment: preliminary report. *European Journal of Obstetrics, Gynecology, and Reproductive Biology*, 87, 35-37.
99. Gerli, S., Rossetti, D., Pacifici, A., Aviles, E., Dominici, C., Mattei, A., & Di Renzo, G. C. (2001). Hysterectomy for the transsexual. *Journal of the American Association of Gynecologic Laparoscopists*, 8, 613-614.
100. Saridogan, E., & Cutner, A. (2004). The use of McCartney tube during total laparoscopic hysterectomy for gender reassignment: A report of two cases. *BJOG: an International Journal of Obstetrics and Gynecology*, 111, 277-278.
101. Hage, J. J., Bouman, F. G., & Bloem, J. J. A. M. (1993). Construction of the fixed part of the neourethra in female-to-male transsexuals: Experience in 53 patients. *Plastic and Reconstructive Surgery*, 91, 904-910.
102. Hage, J. J., Torenbeek, R., Bouman, F. G., & Bloem, J. J. A. M. (1993). The anatomic basis of the anterior vaginal flap used for neourethra construction in female-to-male transsexuals. *Plastic and Reconstructive Surgery*, 92, 102-108.
103. Levine, L. A., & Elterman, L. (1998). Urethroplasty following total phallic reconstruction. *Journal of Urology*, 160, 378-382.
104. Hage, J. J., Bouman, F. G., & Bloem, J. J. A. M. (1993). Preconstruction of the pars pendulans urethrae for phalloplasty in female-to-male transsexuals. *Plastic and Reconstructive Surgery*, 91, 1303-1307.
105. Ralph, D. J. (1999). Urethral complications in phalloplasty. *Boys' Own – UK*, 30, 16-18. Retrieved January 1, 2005, from <http://www.transgenderzone.com/library/pr/fulltext/32.htm>.

106. Rohrmann, D., & Jakse, G. (2003). Urethroplasty in female-to-male transsexuals. *European Urology*, *44*, 611-614.
107. Hage, J. J. (1996). Metaidoioplasty: An alternative phalloplasty technique in transsexuals. *Plastic and Reconstructive Surgery*, *97*, 161-167.
108. Perovic, S. V., & Djordjevic, M. L. (2003). Metoidioplasty: A variant of phalloplasty in female transsexuals. *BJU International*, *92*, 981-985.
109. Hage, J. J., Bloem, J. J. A. M., & Suliman, H. M. (1993). Review of the literature on techniques for phalloplasty with emphasis on the applicability in female-to-male transsexuals. *Journal of Urology*, *150*, 1093-1098.
110. Gilbert, D. A., Schlossberg, S. M., & Jordan, G. H. (1995). Ulnar forearm phallic construction and penile reconstruction. *Microsurgery*, *16*, 314-321.
111. Khouri, R. K., & Casoli, V. M. (1997). Reconstruction of the penis. In S. J. Aston, R. W. Beasley, & C. H. M. Thorne (Eds.), *Grubb and Smith's Plastic Surgery* (5th ed., pp. 1111-1119). Philadelphia, PA: Lippincott-Raven Publishers.
112. Gilbert, D. A., Gilbert, D. M., Jordan, G. H., Schlossberg, S. M., & Chesson, R. R. (1998). Ulnar forearm free flap for phallic construction in transsexuals. In R. M. Ehrlich, G. J. Alter, & R. Zorab (Eds.), *Reconstructive and plastic surgery of the external genitalia: Adult and pediatric* (pp. 319-326). Philadelphia, PA: Saunders.
113. Hage, J. J. (1999). Surgical formation of the glans in phalloplasty. In R. M. Ehrlich, G. J. Alter, & R. Zorab (Eds.), *Reconstructive and plastic surgery of the external genitalia: Adult and pediatric* (pp. 361-364). Philadelphia, PA: Saunders.
114. Jordan, G. H. (2002). Total phallic construction, option to gender reassignment. *Advances in Experimental Medicine and Biology*, *511*, 275-280.
115. Santanelli, F., & Scuderi, N. (2000). Neophalloplasty in female-to-male transsexuals with the island tensor fasciae latae flap. *Plastic and Reconstructive Surgery*, *105*, 1990-1996.
116. Chang, T. S., & Hwang, W. Y. (1986). Forearm flap in one-stage reconstruction of the penis. *Plastic and Reconstructive Surgery*, *74*, 251-258.
117. Gottlieb, L. J., & Levine, L. A. (1993). A new design for the radial forearm free-flap phallic construction. *Plastic and Reconstructive Surgery*, *92*, 276-283.
118. Hage, J. J., & de Graaf, F. H. (1993). Addressing the ideal requirements by free flap phalloplasty: Some reflections on refinements of technique. *Microsurgery*, *14*, 592-598.
119. Veselý, J., Kucera, J., Hrbaty, J., Stupka, I., & Rezai, A. (1999). Our standard method of reconstruction of the penis and urethra in female to male transsexuals. *Acta Chirurgiae Plasticae*, *41*, 39-42.
120. Hage, J. J., Winters, H. A. H., & Van Lieshout, J. (1996). Fibula free flap phalloplasty: Modifications and recommendations. *Microsurgery*, *17*, 358-365.
121. Mutaf, M. (2000). A new surgical procedure for phallic reconstruction: Istanbul flap. *Plastic and Reconstructive Surgery*, *105*, 1361-1370.
122. Sengezer, M., & Sadove, R. C. (1993). Scrotal construction by expansion of labia majora in biological female transsexuals. *Annals of Plastic Surgery*, *31*, 372-376.
123. Mulcahy, J. J. (2003). Use of penile implants in the constructed neophallus. *International Journal of Impotence Research*, *15*, S129-S131.

124. Hage, J. J., Bloem, J. J. A. M., & Bouman, F. G. (1993). Obtaining rigidity in the neophallus of female-to-male transsexuals: A review of the literature. *Annals of Plastic Surgery, 30*, 327-333.
125. Hage, J. J., de Graaf, F. H., Bouman, F. G., & Bloem, J. J. A. M. (1993). Sculpturing the glans in phalloplasty. *Plastic and Reconstructive Surgery, 92*, 157-161.
126. Hage, J. J., Bout, C. A., Bloem, J. J. A. M., & Megens, J. A. (1993). Phalloplasty in female-to-male transsexuals: what do our patients ask for? *Annals of Plastic Surgery, 30*, 323-326.
127. Hage, J. J. (1992). *From penioplastica totalis to reassignment surgery of the external genitalia in female-to-male transsexuals*. Amsterdam: Vrije University Press.
128. Hage, J. J., Bouman, F. G., & Bloem, J. J. A. M. (1993). Constructing a scrotum in female-to-male transsexuals. *Plastic and Reconstructive Surgery, 91*, 914-921.
129. Benet, A. E. & Melman, A. (1999). Gender dysphoria and creation of the neo-phallus. In W. J. G. Hellstrom (Ed.), *Handbook of Sexual Dysfunction* (pp. 102-105). Lawrence, KS: American Society of Andrology.
130. Hage, J. J., Bouman, F. G., de Graaf, F. H., & Bloem, J. J. A. M. (1993). Construction of the neophallus in female-to-male transsexuals: The Amsterdam experience. *Journal of Urology, 149*, 1463-1468.
131. Fang, R. H., Kao, Y. S., Ma, S., & Lin, J. T. (1999). Phalloplasty in female-to-male transsexuals using free radial osteocutaneous flap: A series of 22 cases. *British Journal of Plastic Surgery, 52*, 217-222.
132. Hoffman, M. S., Lynch, C., Lockhart, J., & Knapp, R. (1999). Injury of the rectum during vaginal surgery. *American Journal of Obstetrics and Gynecology, 181*, 274-277.
133. Gilbert, D. A., Jordan, G. H., Devine, C. J., Jr., & Winslow, B. H. (1992). Microsurgical forearm "cricket bat-transformer" phalloplasty. *Plastic and Reconstructive Surgery, 90*, 711-716.
134. Hage, J. J. (1997). Dynaflex prosthesis in total phalloplasty. *Plastic and Reconstructive Surgery, 99*, 479-485.
135. Khouri, R. K., Young, V. L., & Casoli, V. M. (1998). Long-term results of total penile reconstruction with a prefabricated lateral arm free flap. *Journal of Urology, 160*, 383-388.
136. Selvaggi, G., Ceulemans, P., De Cuypere, G., Van Landuyt, K., Blondeel, P., Hamdi, M., Bowman, C., & Monstrey, S. (2005). *Subcutaneous mastectomy in the FTM transsexual: An algorithm for choosing the best technique*. Manuscript submitted for publication.
137. Colic, M. M. & Colic, M. M. (2000). Circumareolar mastectomy in female-to-male transsexuals and large gynecomastias: A personal approach. *Aesthetic Plastic Surgery, 24*, 454.

# Appendix A: Resources

## Transgender Health Program

The Transgender Health Program is an anonymous and confidential free service for anyone in BC who has a transgender health question or concern.

Services for clinicians include:

- training in transgender medical and social care
- assistance in care planning
- information about best practice guidelines and standards of care
- assistance with development of trans-inclusion policies and procedures
- information about transgender health research findings and implications for practice
- joint program planning and research initiatives

Services for transgender people and loved ones include:

- help finding health/social services, and assistance to navigate health/social service systems
- information about best practice guidelines, standards of care, and client/patient rights
- peer-based exploration of gender identity, gender expression, and life stresses in a non-judgmental setting
- support and information for family members, partners, friends, and other loved ones
- free condoms and needle exchange
- outreach to transgender people working in the survival sex trade
- information about transgender community organizations and peer support groups

The Transgender Health Program is an initiative of Vancouver Coastal Health.

**For more information, contact:**

Transgender Health Program  
Three Bridges Community Health Centre  
#301-1290 Hornby Street, Vancouver, BC V6Z 1W2  
Phone/TTY/TDD: 604-734-1514 or 1-866-999-1514 (toll-free in BC)  
Fax: 604-633-4241  
Email: [transhealth@vch.ca](mailto:transhealth@vch.ca)  
Web: <http://www.vch.ca/transhealth>

## Harry Benjamin International Gender Dysphoria Association

<http://www.hbigda.org>

The Harry Benjamin International Gender Dysphoria Association (HBI-GDA) is a professional organization devoted to the understanding and treatment of gender dysphoria, with 350 members from around the world in fields such as psychiatry, endocrinology, surgery, psychology, sexology, counseling, sociology, and law. HBI-GDA provides opportunities for scientific interchange among professionals through biennial conferences and publications, and develops and publishes Standards of Care.